

Histopathological confirmation of disseminated larvae (iL3) of *Strongyloides ratti* in an immunosuppressed Wistar rat

Mahmuda, A.^{1,2}, Al-Zihiry, K.J.K.³, Roslaini, A.M.¹, Rukman, A.H.¹, Abdulhaleem, N.^{1,4}, Bande, F.⁵, Mohammed, A.A.², Alayande, M.O.², Abdullah, W.O.⁶ and Zasmy, U.^{1*}

¹Department of Medical Microbiology and Parasitology, Faculty of Medicine and Health Sciences, Universiti Putra Malaysia, Malaysia

²Department of Parasitology and Entomology, Faculty of Veterinary Medicine, Usmanu, Danfodiyo University, Sokoto, Nigeria

³Department of Microbiology, College of Medicine, University of Thi-Qar, Iraq

⁴Department of Biology, College of Science, University of Anbar, Anbar, Iraq

⁵Department of Pathology and Microbiology, Faculty of Veterinary Medicine, Universiti Putra Malaysia

⁶Faculty of Medicine and Health Sciences, Islamic Science University Malaysia, Malaysia

*Corresponding author e-mail: ngah@upm.edu.my

Received 26 April 2016; received in revised form 6 September 2016; accepted 10 September 2016

Abstract. Human strongyloidiasis research requires a large supply of *Strongyloides stercoralis*. This can be achieved through in vivo maintenance of *Strongyloides stercoralis* in *Meriones unguiculatus*, but isolating a large quantity of *Strongyloides stercoralis* to establish the colony from an infected patient is too difficult to achieve. Hence, *Strongyloides ratti* have been used as a model in human strongyloidiasis research. This study describes a successful establishment and maintenance of *Strongyloides ratti* infection in experimentally immunosuppressed Wistar rats. Large quantities of filariform (iL3) larvae of *Strongyloides ratti* for research related to human strongyloidiasis have been harvested following this protocol. Molecular detection method based on PCR using species specific primers was used to confirm the species of the harvested infective larvae (iL3). Additionally, the identification of histopathological lesions confirmed the presence of infective larvae (iL3) in the liver and lungs as a result of an increased parasite burden due to hyperinfection and disseminated disease. This pathological presentation was found to be similar to that reported in *Strongyloides stercoralis*-infected immunocompromised human subjects.

INTRODUCTION

Human strongyloidiasis is a potentially dangerous nematode parasitic infection, especially in immunocompromised individuals of the tropical and sub-tropical regions (Olsen *et al.*, 2009; Schar *et al.*, 2013). It is caused by *Strongyloides stercoralis* which is relatively the smallest nematode parasite in humans that is carried through the circulatory system and completing its life cycle in the tissues of infected host (Ardiç, 2009). *In vivo* maintenance of *S. stercoralis* has been reportedly done in gerbils

(*Meriones unguiculatus*) in a controlled laboratory environment (Shariati *et al.*, 2010). However, this can only be achieved if high quantities of infective larvae (iL3) of *S. stercoralis* are successfully isolated from an infected human patient as required for the subcutaneous inoculation of *Meriones unguiculatus*. This process can be tedious and time consuming (Nolan *et al.*, 2002), compared to the large quantities of infective larvae (iL3) of *Strongyloides ratti* which is much easier to isolate from naturally infected wild rats (*Rattus* spp). Interestingly, *Strongyloides ratti* is a helminth commonly

found in wild rodents that is morphologically and phylogenetically related to *Strongyloides stercoralis* which infects human beings (Dorris *et al.*, 2002; Matsuda *et al.*, 2003). Due to these similarities, *S. ratti* has been used as a model for human strongyloidiasis research.

The infection by *Strongyloides stercoralis* is usually asymptomatic in immunocompetent individuals and is characterized by lack of visible clinical signs (Mir *et al.*, 2006). Studies have shown that *S. stercoralis* hyperinfection syndrome resulted from repeated autoinfection cycles caused by the alteration in the immune system of the host (Siddiqui and Berk, 2001; Ferreira, 2003; Gill *et al.*, 2004; Concha *et al.*, 2005). The hyperinfection syndrome is manifested by the presence of signs and symptoms attributable to the increased larval migration in tissues and detection of increased numbers of eggs or rhabditiform larvae in faeces and or sputum (Lam *et al.*, 2006). A fatal disease caused by the hyperinfection syndrome often refers to the migration of larvae to other organs beyond the confines of the pulmonary autoinfection route (Keiser & Nutman, 2004). Prolonged therapy with corticosteroids triggers accentuated immunosuppressive effects and are a major contributing risk factor for the transformation from chronic strongyloidiasis to hyperinfection syndrome leading to disseminated strongyloidiasis, which has a high mortality ratio (Fardet *et al.*, 2007; Al Maslamani *et al.*, 2009; Marcos *et al.*, 2011), especially in patients with auto-immune diseases (Altintop *et al.*, 2010) and other inflammatory conditions (Basile *et al.*, 2010).

This study is aimed to establish and maintain *Strongyloides ratti* infection in an experimental animal model (corticosteroid-immunosuppressed Wistar rat) for future human strongyloidiasis research and also to confirm that the rats under immunosuppression would present the two parameters of severe infection, that is, hyperinfection and tissue dissemination.

Ethical Approval

Strongyloides ratti infection model was established and maintained in an approved animal facility. Use of animals in this experiment was approved by and conducted in accordance with the guidelines of the Institutional Animal Care and Use Committee (IACUC), Faculty of Medicine and Health Sciences, Universiti Putra Malaysia, Serdang Malaysia (UPM/FPSK/PADS/BR-UUH/00247).

Trapping naturally infected wild rats (*Rattus spp.*)

Trapping of wild rats was done using steel mouse traps. Traps were set up near and around commonly used dump sites at several locations and were checked regularly. The captured rats were taken to the animal experimental unit and maintained in cages individually with supply of food and water *ad libitum*. Fecal samples were collected and examined for eggs and later cultured to harvest the infective filariform larval stages (iL3).

Culture of *Strongyloides ratti* eggs

Modified fecal filtration technique (MFFT) based on Harada Mori technique was conducted using clean plastic petri dishes and filter paper. Collected fecal pellets of wild rats were thoroughly mixed in 50 ml clean conical tubes with tap water until completely emulsified. Fecal emulsion was spread over double layered of 90 mm Whatman filter paper (GE Healthcare, UK) on an absorbable tissue paper inside a fume hood. Filter paper containing the fecal emulsion was then transferred to clean 90 X 15 mm petri dishes, ensuring that there was no excess moisture, covered, sealed with parafilm and properly labelled. The culture dishes were then incubated at 28°C for 3 days for the harvesting of newly generated infective iL3 larvae through washings and microscopic examination (Al-zihiry *et al.*, 2015).

Morphological identification of *Strongyloides ratti*

Fecal smear and wet mount methods were conducted for the detection of eggs and rhabditiform larvae. The fecal culture technique was performed for the identification of filariform larvae and free-living adults. The morphology of the different observed stages was then compared with those described in the literature to allow proper identification. Some slides were stained with Lugol's iodine to clearly examine the internal structures of the stages. The detected stages of the parasite were analyzed using image analysis software (Nikon Corporation, Japan).

Molecular identification of *Strongyloides ratti*

In order to re-confirm the results of the microscopic examination of the morphology of *Strongyloides ratti*, PCR technique was utilized. This technique was used to confirm the species-specific 28S rDNA gene of *Strongyloides ratti* in worm-egg positive fecal samples from the established *in vivo* murine model of *Strongyloides ratti* infection in Wistar rats.

Extraction of genomic DNA from feces of infected rats (*Rattus* spp.)

Fecal samples collected from the infected rats were examined for the presence of *Strongyloides ratti* eggs. Positive samples were selected for genomic DNA extraction for PCR assay. Genomic DNA was extracted using QIAamp® DNA stool MiniKit according to the manufacturer's instructions (QIAGEN, Hilden, Germany). Briefly, about 200 mg of stool samples were used and the concentration (ng/μl) of the eluted DNA was checked using a NANODROP Spectrophotometer (Thermo Scientific, USA). The extracted genomic DNA was finally aliquoted (10 μl) in Eppendorf tubes and kept at -20°C until use (Verweij *et al.*, 2009; Pakdee *et al.*, 2012).

PCR amplification of *Strongyloides ratti* 28S rDNA gene

Two sets of designed species-specific primers were used to amplify the 28S rDNA

of *Strongyloides ratti*. Forward StroS (5'-TTAGAGTCGTGTTGCTTGGAA-3') and reverse StroAS (5'-GTGCAACTGGCTCTGTATGC-3') primer pair were designed based on rDNA sequences published in GenBank (Accession U39490) which amplify at 180 bp. PCR reactions were performed using DreamTaq Green PCR Master Mix (2X) (Thermo Fisher Scientific, USA), 100 nmol of each primer, 1 μl of template DNA, and DNA-free water up to final volume of 25 μl under the following conditions: 1 cycle at 95°C for 5 min (time-delay), 30 cycles at 95°C for 5 sec (denaturation), 60°C for 20 sec (annealing) and 72°C for 30 sec (extension), followed by a final extension of 72°C for 5 min was performed (Ten Hove *et al.*, 2009). The PCR product was sent for DNA sequencing and analyzed for homology using NCBI Basic Local Alignment Search Tool (BLAST).

Gel Electrophoresis

The PCR products were loaded at 1.5% TBE (Bio Basic Incorporation, Canada) on an agarose gel electrophoresis at 70 volts for 65 min. Gels were visualized under UV light transilluminator (Major Science, USA), and photographed to confirm the size of the PCR amplicons using 100 bps DNA ladder as markers. (GeneDirex, Taiwan).

Establishment of *Strongyloides ratti* infection in experimental Wistar rats

Six weeks old anesthetized rats were inoculated with 2,500 infective filariform (iL3) larvae of *Strongyloides ratti* by subcutaneous injection on the dorsum of the neck. Fecal pellets were collected (per rectum) after 7 days post-inoculation and were cultured for confirmation and quantification of infective larvae (Kotze *et al.*, 2004).

Maintenance of *Strongyloides ratti* infection in experimental Wistar rats

The infection in experimental Wistar rats was maintained by oral administration of prednisolone at 0.25 mg/kg body weight, every other day over a period of one month (Fenton *et al.*, 2004; Tazir *et al.*, 2009). This was to induce an experimental immuno-

suppression to mimic that in humans for the establishment of hyperinfection and disseminated strongyloidiasis. The drug was administered orally using an 18 gauge rodent feeding tube following manual restrain.

Histopathological examination of tissues

Tissues (approximately 1.0 cm in length) from both lung and liver were fixed in 10% formalin, dehydrated, cleared in absolute alcohol/xylene and embedded in paraffin according to standard protocol (Matsuda *et al.*, 2003). A non-infected and non-treated rat from the control group was randomly selected and humanely killed with chloroform and dissected for comparison with normal tissue histology. Histopathological sections were cut in 4 μ m thickness, and stained with haematoxylin-eosin (HE) prior to examination. The slides were microscopically examined at different magnifications to assess the histological and pathological alterations and to investigate the presence of infective larvae (iL3) in the organs.

RESULTS

In vivo maintenance of *Strongyloides ratti* in immunosuppressed Wistar rats

Strongyloides ratti infection was established and maintained in Wistar rats as an experimental model for strongyloidiasis research. Large number of larvae was successfully harvested using a modified fecal filtration (MFF) technique based on the Harada Mori's technique. Infective filariform larvae (iL3), were harvested from coprocultures as early as seven days post-inoculation of ten rats. The larval count decreased substantially to 20,000 iL3 following one week of continuous fecal culture. The larval counts have increased to 200,000 iL3 after daily administration of prednisolone for 10 days post-inoculation. There was a drastic decrease (post-treatment) in the larval harvest to 60,000 iL3 in the last ten days of the experiment (Figure 1).

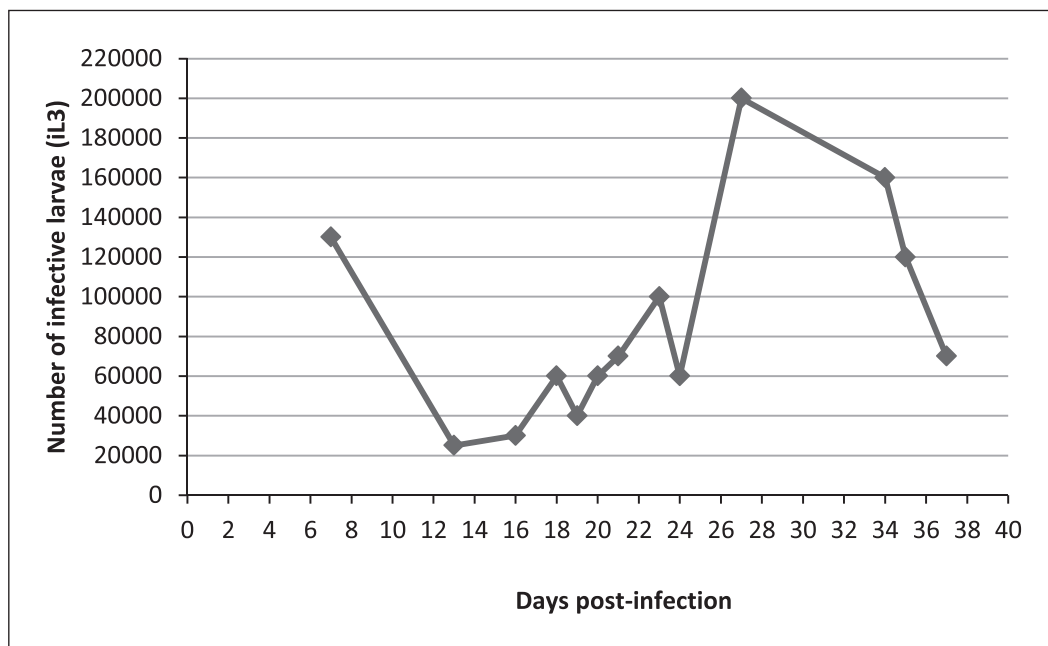


Figure 1. Number of infective larvae (iL3) obtained from fecal cultures by modified fecal filtration technique from infected rats treated with prednisolone.

Morphological identification of *Strongyloides ratti*

Different stages in the life cycle of this nematode parasite were identified based on their morphological characteristics as described by Speare, (1989). The eggs are thin-shelled, transparent and oval in shape. The eggs contain active rhabditiform larvae that were ready to hatch (Plate: 1A). Rhabditiform larvae were found to be short, broad and stumpy with a rhabditiform oesophagus measuring about one-third ($1/3$) of their total length. The tail was pointed but not filamentous and the tip was not notched as shown in Plate: 1B.

The oesophagus in filariform larvae is similar to that in parasitic females with a length approximately 40% that of its body length (Plate 2). The filariform larvae were identified based on their morphological characteristic appearance of being long and slender, a filariform oesophagus measuring around a half ($1/2$) of their total length (A) and with notched tail tip (A).

Free-living adults (male/female) worms were also identified based on the description of Speare, (1989). Both sexes are broader and longer in length, with a rhabditiform oesophagus and a blunt-end tail. The free-living adult males are usually shorter than

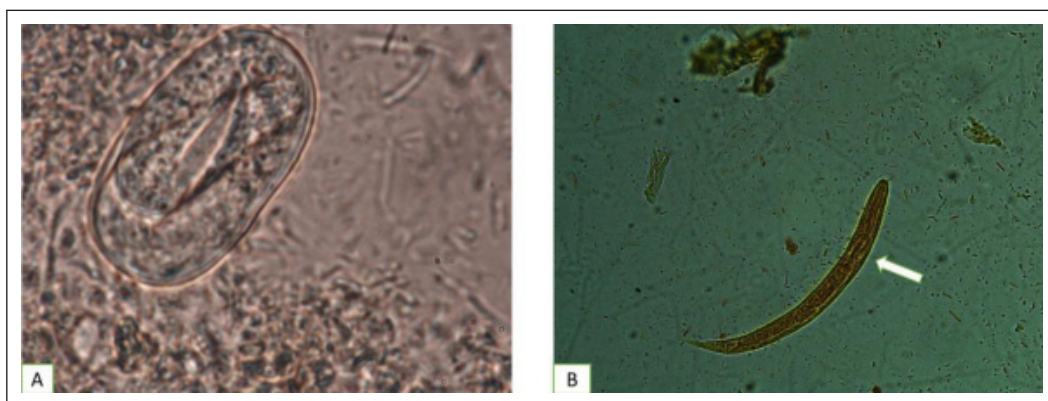


Plate 1. A: Eggs of *Strongyloides ratti* from fecal samples of infected rats identified by direct fecal smear method (100X); B: Rhabditiform larva of *Strongyloides ratti* with a rhabditiform oesophagus (arrow) that extends only to about one-third ($1/3$) of its total length (20X, stained).

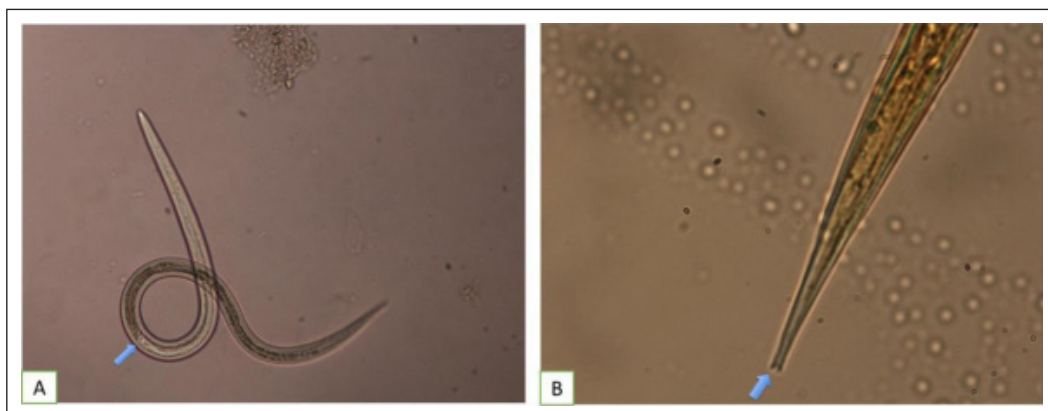


Plate 2. A: Filariform larva of *Strongyloides ratti* showing its filariform oesophagus (arrow) that extends to nearly half ($1/2$) the total length (20X); B: Filariform larva of *Strongyloides ratti* (stained) showing its characteristic tripartite or notched-tail (arrow) appearance at the tip of the tail (100X).

the females and have a curved or hooked-like tail appearance following staining with lugol's iodine, while the females have a straight and pointed tail even after staining and permanently mounted on the slide (Plate 3).

Molecular characteristics of *Strongyloides ratti*

A 180 bp amplified band was obtained via electrophoresis of the PCR product from the extracted DNA (Plate 4). The results of the sequence analysis revealed 97% similarity to *Strongyloides stercoralis* (SS U39489) and

Strongyloides ratti (SRU39490) using Basic Local Alignment Search Tool (BLAST) while comparing with other similar *Strongyloides* species deposited in the NCBI database.

Pathology and symptoms

Histopathological analysis revealed no migrating larvae in the tissues (lung and liver) of infected rats without the administration of prednisolone at 0.25 mg/kg body weight (Rat A). But there was severe diffused haemorrhages, congested blood vessels and massive inflammatory (eosinophilic) cellular infiltration in the lung

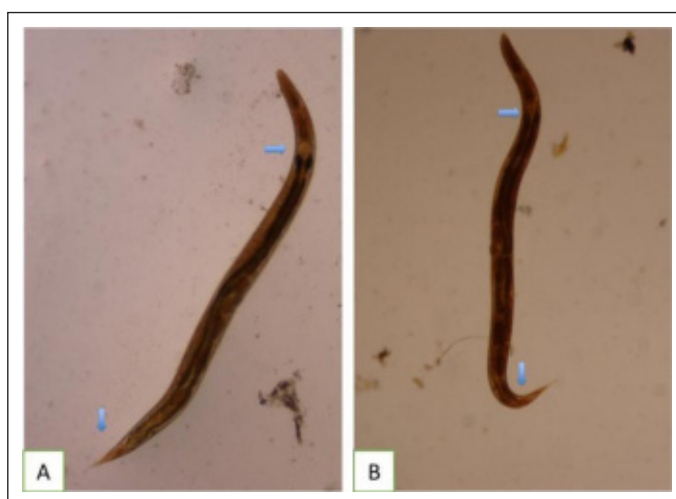


Plate 3. A: Free-living adult female *Strongyloides ratti* with pointed tail tip (A); B: Free-living adult male *Strongyloides ratti* with curved tail tip, both showing a rhabditiform oesophagus (top arrow).

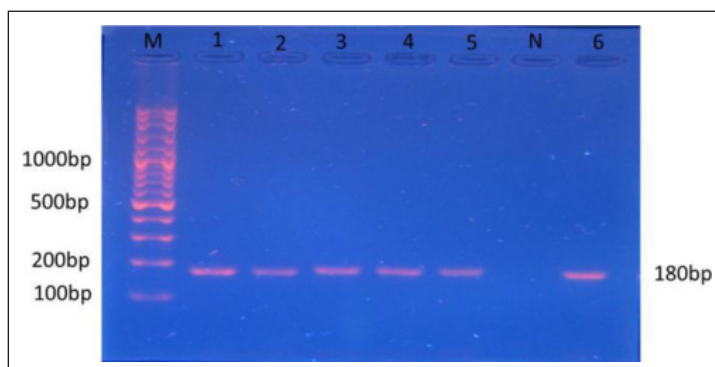


Plate 4. Agarose gel electrophoresis: PCR amplification of 28S rDNA gene using universal primer; M: 100 bp DNA Ladder; 1 - 6: PCR products from selected samples (180 bp); N: Negative control.

(Plate 5). In the liver, there was passive congestion with blood pools around the central veins (Plate 6). Histopathology of the lungs and liver of the infected and with the administration of prednisolone at 0.25 mg/kg body weight rat (Rat B) showed migrating larvae of *Strongyloides ratti* in tissues of the organs. The tissue of the lungs revealed dissemination of larvae in the alveolar space accompanied by massive hemorrhages, and mild cellular infiltration (Plate 7). In the liver, larvae were found in portal tracts and in

periportal areas, with mild cellular infiltration (Plate 8).

DISCUSSION

Considering the difficulty associated with *in vivo* maintenance of experimental *Strongyloides stercoralis* for adequate isolation of a significant number of infective larvae (iL3) together with the significant risk of the research personnel with accidental

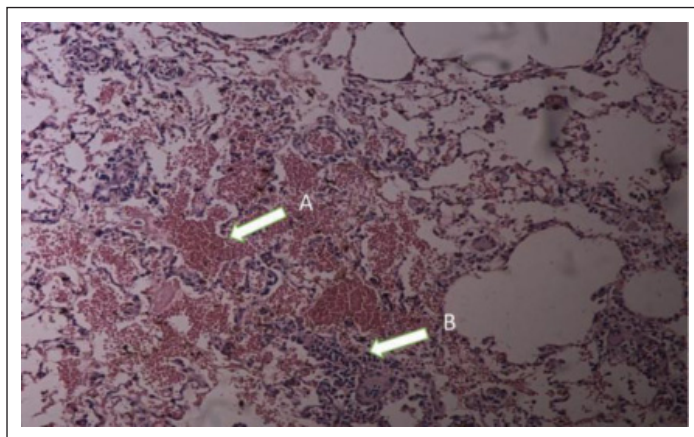


Plate 5. Photomicrograph of the lung section (Rat A) showing diffused hemorrhages (arrow A) and massive inflammatory (eosinophilic) cellular infiltration (arrow B). (Magnification X10).

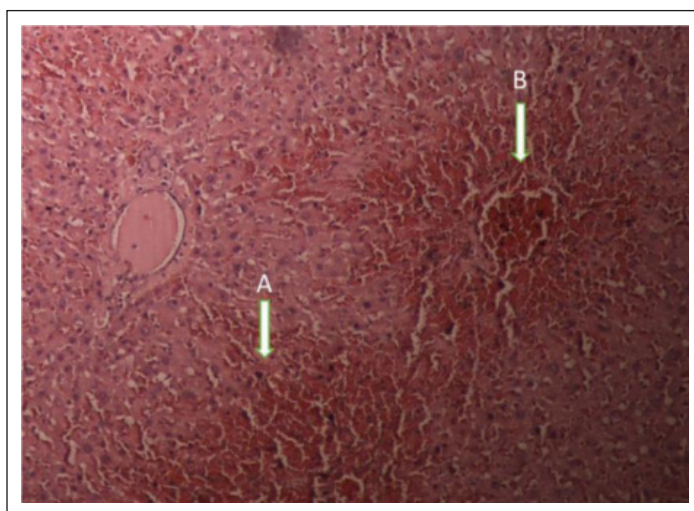


Plate 6. Photomicrograph of liver sections (Rat A) showing passive congestion (arrow A) with blood pools around the central veins (arrow B). (Magnification X10).

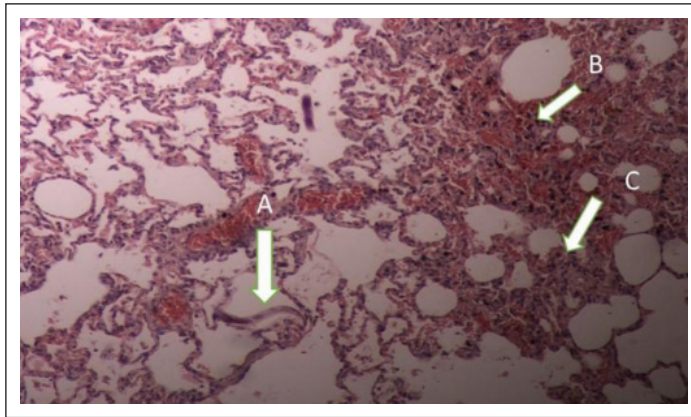


Plate 7. Photomicrograph of the lung section (Rat B) showing infective larva of *Strongyloides ratti* (arrow A) in the alveolar space with hemorrhages (B) and mild cellular infiltration (arrow C). (Magnification X10).

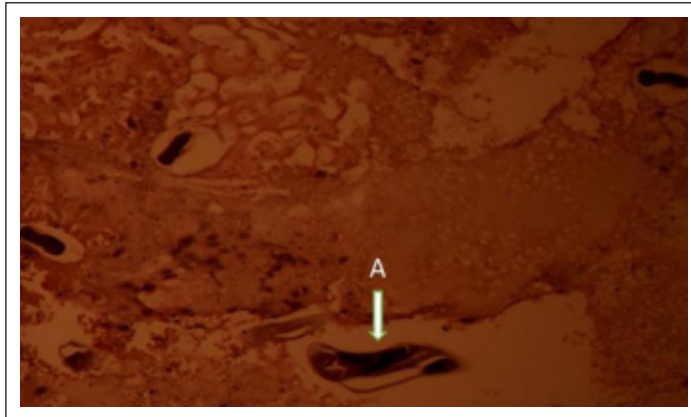

Plate 8. Photomicrograph of liver sections (Rat B) showing infective larva (arrow A) of *Strongyloides ratti* in parietal areas of the liver tissues (Magnification X20).

infection, the standardization and utilization of heterologous antigen from *Strongyloides ratti* could be considered as a reliable source of antigen for immunodiagnosis of human strongyloides infections. In this scenario, it is much easier to maintain rats infected with *Strongyloides ratti* than maintaining dogs (Gonçalves *et al.*, 2007) or monkeys infected with *Strongyloides stercoralis*.

The establishment of this infection model in the immunosuppressed rat was neither difficult nor laborious compared to other usually employed laboratory hosts (dogs and monkeys). Infective larvae were recovered

as early as 7 days post-inoculation of the rats. Five weeks were most feasible for the maintenance of the infection, resulting in the harvest of large quantity of infective larvae (iL3) which is required for use as a source of antigen (protein) for animal immunization.

Oral administered prednisolone efficiently induced immunosuppression and resulted in an increased number of eggs in the feces and also an increased number of larval yield. This finding is supported by other related similar published articles. For example, an increased in the egg output of *Strongyloides stercoralis* was detected in

patients with acquired immunodeficiency syndrome, which was attributed to their immunosuppressive condition (Ohnishi *et al.*, 2004). Similar studies have been previously reported with the use of corticosteroids for experimental immuno-suppression of rats infected with *Strongyloides ratti* (Basile *et al.*, 2010) and *Strongyloides venezuelensis* (Tefé-Silva *et al.*, 2008; Machado *et al.*, 2011).

The morphological characteristics of different stages of *Strongyloides ratti* have been similar to the ones already described by other studies conducted on the same rodent species of *Strongyloides* (dos Santos *et al.*, 2010). These reports have shown that *Strongyloides ratti* and *Strongyloides venezuelensis* are morphologically similar in both rhabditiform and filariform larvae. It is very difficult to morphologically distinguish between these species except using molecular techniques, mostly through apomorphic changes in the *Strongyloides venezuelensis* ssrDNA gene sequence (Dorris *et al.*, 2002).

Phylogenetic analysis based on the obtained sequence revealed that *Strongyloides ratti* isolated was 97% similar to the other similar species, including *Strongyloides stercoralis*, deposited in the NCBI database. This has also supported the results of the conventional microscopic examination of the stool samples from the established murine model of *Strongyloides ratti* infection. Other studies have also reported that performing PCR with DNA extracted from stool sample provides highly specific and sensitive results for the detection of *Strongyloides stercoralis* genome in human feces (Verweij *et al.*, 2009; Moghaddassani *et al.*, 2011; Ahmad *et al.*, 2013; Repetto *et al.*, 2016) and *Strongyloides ratti* in fecal pellets from infected rats (Al-zihiry *et al.*, 2015).

The results of the present study revealed hyperinfection and dissemination of infective larvae of *Strongyloides ratti* in the lung and liver of experimentally immunosuppressed rats. Infective larvae were not detected in tissues of the lungs and liver of the non-treated rats with corticosteroid. However, histopathology of the affected lungs revealed

massive alveolar haemorrhages and eosinophilic infiltration, whereas in the liver, there was passive congestion and hemorrhage around the central veins. This is similar to the report by Ardic (2009) who concluded that absence of visible larvae in the tissues could be associated with the probability that there was immunity development against the parasite in the rats over time which may have overcome the effects of the larval migration in tissues or due to short experimental periods and non-prolonged corticosteroids therapy.

The characteristic migrating larvae in the organs (liver and lungs) that were microscopically examined in the infected and treated rats could be attributed to the probability that either the number of infective larvae (iL3) outweighed the strength of the immune system or due to prednisolone induced immunosuppression. Rivero *et al.* (2002) reported that factors such as age, immune status, number of the inoculums, the route of larval presentation and dose/dosage of the immunosuppressant are known to influence the appearance of the larvae in the organs of the infected and treated rats. Although the number of larvae in tissues was not extensive which could be due to the fact that only prolonged corticosteroids therapy could elicit extensive migration of larvae in tissues. The reduction in the number of inflammatory cells in the alveolar space as observed in the organs of the infected and treated rats could be a possibility that prednisolone impaired the host's immune response by decreasing the number of circulating eosinophils and subsequently contributed to the dissemination of the parasites. This has also been documented by Machado and colleagues (2011).

This finding also confirms the migrations of insignificant numbers of infective larvae of *Strongyloides ratti* and *Strongyloides venezuelensis* in several visceral organs (liver, spleen, kidney, lungs) of C57Bl/6 mice and Sprague-Dawley rats, respectively, as describe by Dawkins and Matsuda following percutaneous injection on the anterior abdominal wall and through the oral route as previously reported (Dawkins *et al.*, 1982;

Matsuda *et al.*, 2003). Other studies in experimental models of *Strongyloides venezuelensis* have reported that larvae were surrounded by inflammation mediated cells (eosinophils) and mast cells in the lungs. Infected rats treated with dexamethasone also showed a decreased number of eosinophils in the alveolar space compared to infected, but non-treated rats (Tefé-Silva *et al.*, 2008).

CONCLUSION

In this study, we establish a model for human strongyloidiasis based on maintaining infection of *Strongyloides ratti* in immunosuppressed Wistar rats through larval inoculation and experimental immunosuppression. The results obtained from this study showed that the use of drugs with immunomodulatory effects, such as prednisolone, interferes with the normal pulmonary cycle (morbidity) of *Strongyloides ratti* infection, and may also contribute to the mechanisms involved in the pathogenesis of the disease. The findings of this study have also confirmed the relative similarities in the disease spectrum between *Strongyloides ratti* infection in murine models and *Strongyloides stercoralis* infections in terms of hyperinfection and dissemination. Histopathological findings of *Strongyloides* larvae and eosinophilic lesions remain the only important tool for definitive diagnosis of hyperinfection syndrome and disseminated disease.

COMPETING INTERESTS

The authors declare that they have no competing interests regarding the publication of this paper.

Acknowledgments. This work was supported, in part, by grants from the Ministry of Higher Education Malaysia (04-01-11-1067FR), Ministry of Science, Technology and Innovation Malaysia (02-01-04-SF1655) and Universiti Putra Malaysia (04-02-12-2097RU).

REFERENCES

- Ahmad, A.F., Hadip, F., Ngui, R., Lim, Y.A.L. & Mahmud, R. (2013). Serological and molecular detection of *Strongyloides stercoralis* infection among an Orang Asli community in Malaysia. *Parasitology Research*, **112**: 2811-2816.
- Al Maslamani, M.A., Al Soub, H.A., Al Khal, A.L.M., Al Bozom, I.A., Abu Khattab, M.J. & Chacko, K.C. (2009). *Strongyloides stercoralis* hyperinfection after corticosteroid therapy: A report of two cases. *Annals of Saudi Medicine*, **29**: 397-401.
- Altintop, L., Cakar, B., Hokelek, M., Bektas, A., Yildiz, L. & Karaoglanoglu, M. (2010). *Strongyloides stercoralis* hyperinfection in a patient with rheumatoid arthritis and bronchial asthma: a case report. *Annals of Clinical Microbiology and Antimicrobials*, **9**: 27.
- Al-zihiry, K.J.K., Aliyu, M., Atshan, S.S., Unyah, Z., Ibraheem, Z.O., Majid, R.A., Awang, R. & Abdullah, W.O. (2015). Molecular Detection of *Strongyloides ratti* in Faecal Samples from Wild Rats in Serdang, Malaysia. *Tropical Journal of Pharmaceutical Research*, **14**(7): 1167-1173.
- Ardıç, N. (2009). An overview of *Strongyloides stercoralis* and its infections. *Microbiology Bulletin*, **43**: 169-177.
- Basile, A., Simzar, S., Bentow, J., Antelo, F., Shitabata, P., Peng, S.K. & Craft, N. (2010). Disseminated *Strongyloides stercoralis*: hyperinfection during medical immunosuppression. *Journal of American Academy of Dermatology*, **63**: 896-902.
- Concha, R., Harrington, W. & Rogers, A.I. (2005). Intestinal Strongyloidiasis: recognition, management, and determinants of outcome. *Journal of Clinical Gastroenterology*, **39**(3): 203-211.
- Dawkins, H.J., Thomason, H.J. & Grove, D.I. (1982). The occurrence of *Strongyloides ratti* in the tissues of mice after percutaneous infection. *Journal of Helminthology*, **56**: 45-50.

- Dorris, M., Viney, M.E. & Blaxter, M.L. (2002). Molecular phylogenetic analysis of the genus *Strongyloides* and related nematodes. *International Journal of Parasitology*, **32**: 1507-1517.
- dos Santos, K.R., Carlos, B.C., Paduan, K.S., Kadri, S.M., Barrella, T.H., Amarante, M.R.V., Ribolla, P.E.M. & da Silva, R.J. (2010). Morphological and molecular characterization of *Strongyloides ophidiae* (Nematoda, Strongyloididae). *Journal of Helminthology*, **84**: 136-142.
- Fardet, L., Génereau, T., Poirot, J.L., Guidet, B., Kettaneh, A. & Cabane, J. (2007). Severe Strongyloidiasis in corticosteroid-treated patients: Case series and literature review. *Journal of Infection*, **54**(1): 18-27.
- Fenton, A., Paterson, S., Viney, M.E. & Gardner, M.P. (2004). Determining the optimal developmental route of *Strongyloides ratti*: an evolutionarily stable strategy approach. *Evolution*, **58**: 989-1000.
- Gill, G.V., Welch, E., Bailey, J.W., Bell, D.R. & Beeching, N.J. (2004). Chronic *Strongyloides stercoralis* infection in former British Far East prisoners of war. *Q.J. Med. – Monthly Journal for the Association of Physicians*, **97**: 789-795
- Gonçalves, A.L.R., Machado, G.A., Gonçalves-Pires, M.R.F., Ferreira-Júnior, A, Silva, D.A.O., Costa-Cruz, J.M. (2007). Evaluation of strongyloidiasis in kennel dogs and keepers by parasitological and serological assays. *Veterinary Parasitology*, **147**: 132-9.
- Keiser, P.B. & Nutman, T.B. (2004). *Strongyloides stercoralis* in the immunocompromised population. *Clinical Microbiology Review*, **17**(1): 208-217.
- Kotze, A.C., Clifford, S., O'Grady, J., Behnke, J.M. & Mc Carthy, J.S. (2004). An *in vitro* larval motility assay to determine anthelmintic sensitivity for human hookworm and *Strongyloides* species. *American Journal of Tropical Medicine and Hygiene*, **71**: 608-616.
- Lam, C.S., Tong, M.K., Chan, K.M. & Siu, Y.P. (2006). Disseminated strongyloidiasis: a retrospective study of clinical course and outcome. *European Journal of Clinical Microbiology and Infectious Diseases*, **25**: 14-18.
- Machado, E.R., Carlos, D., Sorgi, C.A, Ramos, S.G., Souza, D.I., Soares, E.G., Costa-Cruz, J.M., Ueta, M.T., Aronoff, D.M. & Faccioli, L.H. (2011). Dexamethasone effects in the *Strongyloides venezuelensis* infection in a murine model. *American Journal of Tropical Medicine and Hygiene*, **84**: 957-66.
- Martin-Rabadan, P., Munoz, P., Palomo, J. & Bouza, E. (1999). Strongyloidiasis: the Harada-Mori test revisited. *Clin. Microbiol. Infect.* **5**: 374-376.
- Marcos, L.A., Terashima, A., Canales, M. & Gotuzzo, E. (2011). Update on strongyloidiasis in the immunocompromised host. *Current Infectious Disease Reports*, **13**(1): 35-46.
- Matsuda, K., Kim, B.S., Whang, I.S., Lim, C.W. & Baek, B.K. (2003). Migration of *Strongyloides venezuelensis* in rats after oral inoculation of free-living infective larvae. *Journal of Veterinary Medical Sciences*, **65**: 971-975.
- Mir, A., Benahmed, D., Igual, R., Borrás, R., O'Connor, J.E., Moreno, M.J. & Rull, S. (2006). Eosinophil-selective mediators in human strongyloidiasis. *Parasite Immunology*, **28**: 397-400.
- Moghaddassani, H., Mirhendi, H., Hosseini, M., Rokni, M., Mowlavi, G. & Kia, E. (2011). Molecular Diagnosis of *Strongyloides stercoralis* Infection by PCR Detection of Specific DNA in Human Stool Samples. *Iranian Journal of Parasitology*, **6**: 23-30.
- Nolan, T.J., Bhopale, V.M., Rotman, H.L., Abraham, D. & Schad, G.A. (2002). *Strongyloides stercoralis*: High worm population density leads to autoinfection in the jird (*Meriones unguiculatus*). *Experimental Parasitology*, **100**: 173-178.

- Ohnishi, K., Kogure, H., Kaneko, S., Kato, Y. & Akao, N. (2004). Strongyloidiasis in a patient with acquired immunodeficiency syndrome. *Journal of infection and chemotherapy*, **10**: 178-180.
- Olsen, A., van Lieshout, L., Marti, H., Polderman, T., Polman, K., Steinmann, P., Stothard, R., Thybo, S., Verweij, J.J. & Magnussen, P. (2009). Strongyloidiasis – the most neglected of the neglected tropical diseases? *Transactions of the Royal Society of Tropical Medicine and Hygiene*, **103**(10): 967-972.
- Pakdee, W., Thaenkham, U., Dekumyoy, P., Nguankiat, S., Maipanich, W. & Pubamben, S. (2012). Genetic differentiation of *Strongyloides stercoralis* from two different climate zones revealed by 18S ribosomal DNA sequence comparison. *Southeast Asian Journal of Tropical Medicine and Public Health*, **43**: 1333-8.
- Repetto, S.A., Ruybal, P., Solana, M.E., Lopez, C., Berini, C.A., Alba Soto, C.D. & Gonzalez Cappa, S.M. (2016). Comparison between PCR and larvae visualization methods for diagnosis of *Strongyloides stercoralis* out of endemic area: A proposed algorithm. *Acta Tropica*, **157**: 169-177.
- Rivero, J.C., Inoue, Y., Murakami, N. & Horii, Y. (2002). Age and sex related changes in susceptibility of Wistar rats to *Strongyloides venezuelensis* infection. *Journal of Veterinary Medical Sciences*, **64**: 519-521.
- Schär, F., Trostorf, U., Giardina, F., Khieu, V., Muth, S., Marti, H., Vounatsou, P. & Odermatt, P. (2013). *Strongyloides stercoralis*: Global Distribution and Risk Factors. *PLoS Neglected Tropical Diseases*, **7**(7): e2288.
- Shariati, F., Pérez-Arellano, J.L., López-Abán, J., El Behairy, A.M. & Muro, A. (2010). Role of angiogenic factors in acute experimental *Strongyloides venezuelensis* infection. *Parasite Immunology*, **32**: 430-439.
- Speare, R. (1989). Identification of species of *Strongyloides*. In *Strongyloidiasis a major roundworm infection of man*, D.I. Grove, ed. (London: Taylor and Francis), pp. 11-84.
- Tazir, Y., Steisslinger, V., Soblik, H., Younis, A.E., Beckmann, S., Grevelding, C.G., Steen, H., Brattig, N.W. & Erttmann, K.D. (2009). Molecular and functional characterisation of the heat shock protein 10 of *Strongyloides ratti*. *Molecular and Biochemical Parasitology*, **168**: 149-157.
- Tefé-Silva, C., Souza, D.I., Ueta, M.T., Floriano, E.M., Faccioli, L.H. & Ramos, S.G. (2008). Interference of dexamethasone in the pulmonary cycle of *Strongyloides venezuelensis* in rats. *American Journal of Tropical Medicine and Hygiene*, **79**: 571-578.
- Ten Hove, R.J., Van Esbroeck, M., Vervoort, T., Van Den Ende, J., Van Lieshout, L. & Verweij, J.J. (2009). Molecular diagnostics of intestinal parasites in returning travelers. *European Journal of Clinical Microbiology and Infectious Diseases*, **28**: 1045-1053.
- Verweij, J.J., Canales, M., Polman, K., Ziem, J., Brienen, E.A.T., Polderman, A.M. & van Lieshout, L. (2009). Molecular diagnosis of *Strongyloides stercoralis* in faecal samples using real-time PCR. *Transactions of the Royal Society of Tropical Medicine and Hygiene*, **103**: 342-346.