

Laboratory findings and clinical characteristics of *Pneumocystis* pneumonia and tuberculosis infection among HIV-infected patients with pulmonary infiltrates in Jakarta, Indonesia

Rozaliyani, A.^{1,2*}, Wiyono, W.H.², Nawas, M.A.², Sjam, R.¹, Adawiyah, R.¹, Tugiran, M.¹ and Wahyuningsih, R.^{1,3}

¹Department of Parasitology, Faculty of Medicine, Universitas Indonesia, Jakarta, Indonesia

²Department of Pulmonology and Respiratory Medicine, Faculty of Medicine, Universitas Indonesia, Persahabatan Hospital, Jakarta, Indonesia

³Department of Parasitology, Faculty of Medicine, Universitas Kristen Indonesia, Jakarta, Indonesia

*Corresponding author e-mail: publikasiANR@gmail.com

Received 3 January 2020; received in revised form 26 August 2020; accepted 1 September 2020

Abstract. *Pneumocystis* pneumonia (PCP) and pulmonary tuberculosis infection (PTB) are important opportunistic infections in HIV-infected patients. The diagnosis remains challenging since *Pneumocystis jirovecii* cannot be cultured, and expectorated-sputum is frequently difficult to obtain. The monoclonal-antibody detection for *P. jirovecii* from induced sputum is promising in diagnosing PCP. This study determined the percentage of PCP in HIV-infected patients with pulmonary infiltrates at three government hospitals in Jakarta. The concurrent infection of PTB was carefully documented as well. This cross-sectional study was carried out by documenting the clinical symptoms, laboratory findings, chest X-ray, while clinical outcomes were evaluated during hospitalization. The sputum induction was conducted for *P. jirovecii* with monoclonal antibody detection at the laboratory of Parasitology Department, Faculty of Medicine Universitas Indonesia, as well as Ziehl-Nielsen staining for PTB. The results indicated that of 55 HIV-infected patients with pulmonary infiltrates, the positive monoclonal antibody for *P. jirovecii* was detected in eight patients (14.6%). Weight loss, fever, shortness of breath, and crackles were found in all PCP patients; while dry cough in five patients. Moreover, PTB cases with positive acid-fast bacilli (AFB) was detected in five patients (9.1%), the PTB cases with negative AFB was 43.6% (24 out of 55 patients), and the rest 26 patients (47.3%) were not proven to have PTB. The concurrent infections of PCP and PTB were documented in three out of five positive AFB patients. The clinical outcome of eight PCP patients showed improvement in five patients, but the other three patients died. Laboratory findings play an important role in the diagnosis of PCP and PTB, along with clinical characteristics and radiological features. Low CD4⁺ cell count was considered a possible risk factor for PCP and poor clinical outcomes.

INTRODUCTION

Pneumocystis pneumonia (PCP) and pulmonary tuberculosis (PTB) are common pulmonary infections in HIV-infected patients; furthermore, their frequencies depend on geographical region. *Pneumocystis jirovecii*, formerly known as *P. carinii*, is the most frequent cause of opportunistic pneumonia in patients with

HIV in the United States and European countries before Highly Active Anti Retrovirus Therapy (HAART) era and cotrimoxazole as PCP prophylaxis. Conversely, PCP is less frequently reported in developing countries, while PTB and bacterial pneumonia still become the leading causes of death in AIDS patients. Some studies showed an increasing prevalence of PCP in HIV-infected patients in developing

countries, such as India, Sub-Saharan Africa, Thailand, South Korea, and the Philippine (de Arna Rodriguez *et al.*, 2011; Benito *et al.*, 2012; Pandey S *et al.*, 2019) Indonesia has the third-highest TB burden in the world and the increasing number of HIV-infected patients (Trinh *et al.*, 2015), but data on PCP and concurrent infection with PTB is still a lack.

The diagnosis of PCP remains a challenge since clinical symptoms, routine laboratory and radiology features are not typical, just as PTB. *Pneumocystis* spp. has yet to be cultured, so diagnosis depends on the discovery of this fungi on direct examination with staining. Monoclonal antibody detection of *P. jirovecii* has improved diagnostic sensitivity and specificity, compared to conventional staining. The clinical specimen from broncho-alveolar lavage (BAL) or trans-bronchial biopsy remains the gold standard, but those procedures are invasive, require special skills, cost-prohibitive, and not all hospitals have the facilities. Therefore, sputum induction with hypertonic saline is recommended because it is easier, cheaper, less invasive, and has good equality in diagnosis (Choe *et al.*, 2014; Kaur *et al.*, 2015). An elevated level of serum lactate dehydrogenase (LDH) is frequently associated with PCP in HIV-infected patients, documented in 90% of patients (Vogel *et al.*, 2011). This study aimed to determine the percentage of PCP cases among HIV-infected patients with pulmonary infiltrates at three government hospitals in Jakarta. The concurrent infection of PTB was also documented, along with the possible risk factors and clinical outcomes.

MATERIALS AND METHODS

This cross-sectional study was conducted on inpatient wards at three government hospitals in Jakarta: Persahabatan Hospital, Cipto Mangunkusumo Hospital, and Dharmais Hospital. Subjects were patients aged 15 years or older, proven as HIV-infected patients, had symptoms and signs of pneumonia, including pulmonary infiltrates,

and has not received cotrimoxazole as a prophylaxis therapy. The informed consent was signed by all enrolled patients. Ethical approval was received from the ethical committee of Faculty of Medicine, Universitas Indonesia (No. 133/PT02.FK/ETIK/2008). Sputum induction was obtained by inhaled 3% hypertonic saline over 15-20 minutes. The mycological examination was performed at the laboratory of Parasitology Department, Faculty of Medicine Universitas Indonesia. Monoclonal antibody detection with the immunofluorescence staining technique (MONOFLUO™ *Pneumocystis jirovecii* IFA Test Kit #32515) was conducted according to the procedure. Meanwhile, Ziehl-Nielsen staining for PTB was performed as well at the microbiology laboratory of each hospital, according to WHO guidelines (WHO, 2007). Age, gender, HIV status, clinical symptoms, physical examination, laboratory testing, and radiographic features were documented from the medical records, as well as clinical outcomes during hospitalization. The serum lactate dehydrogenase (LDH) was carried out photometrically with reference values of 120-246 IU/L. The relative standard variant has been adjusted as 1-2%, and the upper limit of normal range for LDH is <250 IU/L. The data was collected from July 2008 – February 2009, and the analysis was completed in January 2011. Data were analyzed with SPSS version 17.0 (SPSS Inc., Chicago, IL, USA). The risk factors for PCP were considered by analyzing the association between variables of importance using the Chi-square test and *P*-value < 0.05 was considered as statistically significant.

RESULTS

There were 55 HIV-infected patients met inclusion criteria and hospitalized due to pneumonia symptoms, including pulmonary infiltrates, within one year. Eight of them showed positive results of *P. jirovecii* monoclonal antibody detection. Hence, the percentage of PCP in this study was 14.6%. Furthermore, the percentage of PTB cases with positive AFB was 9.1% (five out of 55 patients), the PTB cases with negative AFB

was 43.6% (24 out of 55 patients), and the rest 26 patients (47.3%) were not proven to have PTB. Meanwhile, concurrent infection of *P. jirovecii* was documented on three out of five PTB patients with positive AFB.

In this study, there were 43 male patients (78.2%) and 12 females (21.8%). The common age group was 20-29 years old and mean age 29.3 ± 5.6 years. Transmission of HIV infection showed 70.9% of patients were intravenous drug users (IVDU). The clinical manifestations of eight PCP patients showed fever, shortness of breath, loss of appetite, weight loss, oral thrush, and crackles in all of them, while dry cough documented in five patients. The laboratory findings of those patients are shown in Table 1. All PCP patients suffered from anemia with hemoglobin (Hb) mean value of 9.15 g/dL. They also had hypoalbuminemia with albumin mean value of 2.58 g/dL. The mean PaO₂ was 77.23 mmHg and the mean O₂ saturation was 93.18%. The serum LDH was elevated with a mean value of 354.38 IU/L. The CD4⁺ levels of all PCP patients showed <50 cells/mm³, while the mean value was 20.13 cells/mm³. Three patients who died showed CD4⁺ values respectively: 5, 10, and 13 cells/mm³.

Radiographic features showed that all PCP patients have radiographic abnormalities, such as diffuse bilateral infiltrates in seven patients, while infiltrates and unilateral pleural effusion found in one patient. The three patients who had concurrent PTB and PCP infections showed significant radiological abnormalities (Figure 1). Clinical outcomes of eight PCP patients revealed

five of them showed an improvement, but the other three patients died. Those three patients were admitted to the hospital with a poor clinical condition, shortness of breath, malnutrition, Hb values <8.5 g/dl, and CD4⁺ cell count <15 cells/mm³. Two patients showed PaO₂ 51.3 and 69.9 mmHg, while one patient had PaO₂ 95.2 mmHg. The extensive chest x-ray abnormality was found in those three patients, and one of them showed diffuse bilateral infiltrates with coarse reticular opacities in both lungs. A few days later she became unconscious and died due to TB meningitis. Risk factors for PCP could not be determined in this study because the statistical tests showed no significant results, but low CD4⁺ cell count was considered as a possible risk factor.

DISCUSSIONS

The increased prevalence of PCP is in line with the increasing number of HIV/AIDS cases in developing countries. The access to PCP prophylaxis therapy or HAART is still limited, and the prevalence was underestimated due to diagnosis limitation (de Arma Rodriguez *et al.*, 2011; Benito *et al.*, 2012; Lowe *et al.*, 2013). Moreover, PTB cases become a global health crisis in many developing countries, including Indonesia that has ranked the third-highest number of TB cases in the world (Trinh *et al.*, 2015).

The percentage of PCP in our study was 14.6% (8 of 55 patients). Meanwhile, the prevalence of PCP in various countries

Table 1. The laboratory results of 55 patients for PCP monoclonal antibody detection

Characteristics	PCP monoclonal antibody detection				P-value
	Positive (n=8)		Negative (n=47)		
	Mean	SD	Mean	SD	
Hb (g/dL)	9,15	1,92	10,00	2,82	0,416*
PaO ₂ (mmHg)	77,24	12,79	86,37	19,82	0,181#
O ₂ saturation (%)	93,18	2,17	94,49	2,66	0,192*
Serum albumin (g/dL)	2,58	0,46	2,81	0,87	0,503#
CD4 ⁺ (cells/mm ³)	20,13	12,56	22,77	26,26	0,720#
Serum LDH (IU/L)	354,38	49,91	341,96	61,44	0,591*

* unpaired t-test, # Mann-Whitney test, SD: standard deviation.

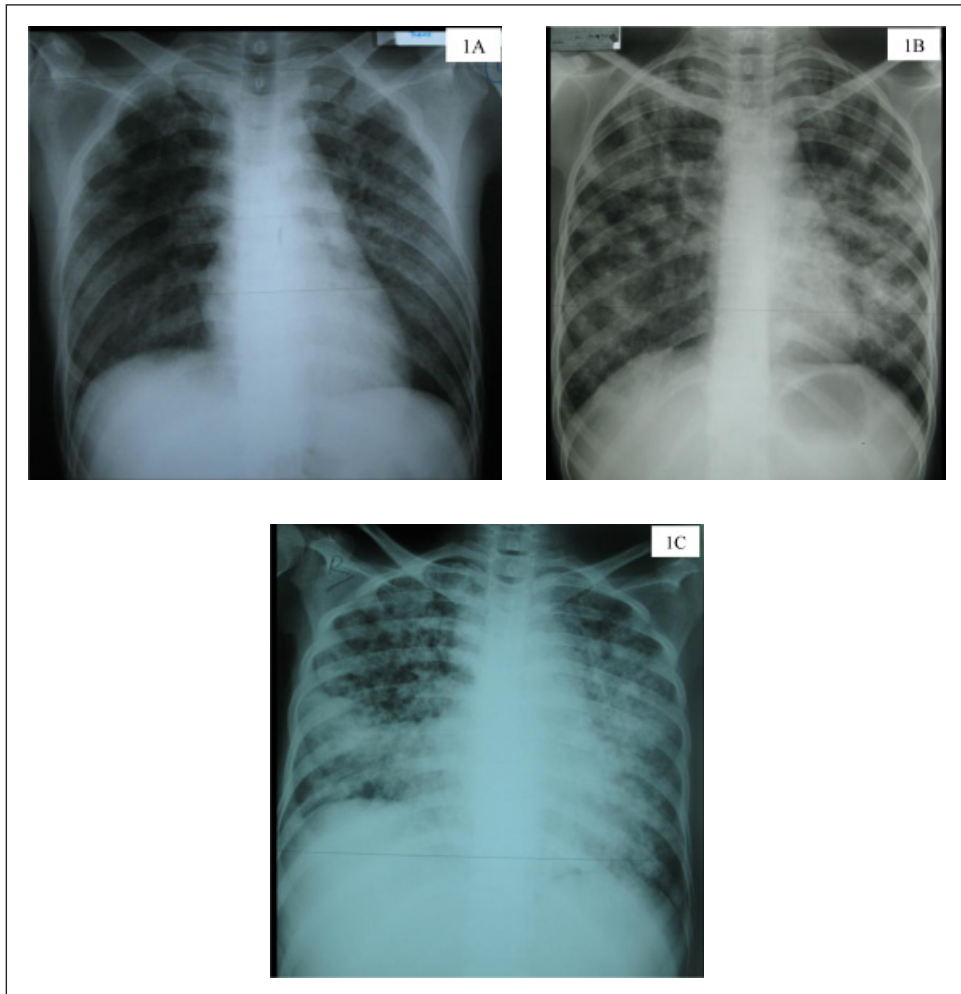


Figure 1. Radiology features of three patients with concurrent PCP and PTB infections.
 1A. The posteroanterior of chest X-ray of a female patient aged 27 years revealed a bilateral pattern of parenchymal opacities, characterized as reticular opacification and ground glass in appearance.
 1B. The posteroanterior of chest X-ray of a male patient aged 30 years depicted multiple patchy shadows with increased density in both lungs which are more obvious in left lung.
 1C. The posteroanterior of chest X-ray of a female patient aged 24 years that showed inhomogeneous consolidation consisting of diffuse bilateral infiltrates with coarse reticular opacities in both lungs.

varies from 10%–30%. The varied range of prevalence rates among studies might be caused by differences in the study design, subjects characteristics, quality of the tests performed, etc. (de Arma Rodriguez *et al.*, 2011; Lowe *et al.*, 2013; Aderaye *et al.* 2007).

The most frequent age group in this study was 20-29 years old which indicated as the most vulnerable group of HIV infection, usually due to lifestyle, as well as many opportunistic infections including PCP. The transmission of HIV infection showed 70.9%

of patients were intravenous drug users (IVDU) and the rest was through sexual contact. Clinical manifestations showed fever, shortness of breath, loss of appetite, weight loss, oral thrush, and crackles in all of eight PCP patients, while dry cough in five patients. The study in Ethiopia reported the clinical symptoms of PCP patients were shortness of breath, dry cough, and weight loss, while crackles were found only in a few patients (Aderaye *et al.*, 2007). Patients affected with *Pneumocystis pneumonia* and

HIV infection tend to present with subacute onset of progressive dyspnea, minimally productive or non-productive cough, malaise, and low-grade fever (Kaur *et al.*, 2015).

Radiographical features of PCP patients in this study showed all patients have radiographic abnormalities, particularly diffuse bilateral infiltrates. Some literature stated that common chest X-ray features in PCP patients are infiltrates mostly reticular or bilateral ground glass in the perihilar. Other radiological findings are focal consolidation, solitary or multiple lung nodules, pleural effusion, pneumothorax, cavities, or calcification (Hardak *et al.*, 2010; Carmona *et al.*, 2011; Crothers *et al.*, 2011).

Examination of blood gas analysis is an important clue in assessing the degree of PCP severity. Hypoxemia can arise due to increased alveolar-arterial oxygen gradient, diffusion capacity problems arise, along with the changes in lung compliance and total lung capacity. In severe pulmonary inflammation, gas exchange disorders will cause hypoxia and decreased lung compliance. Meanwhile, elevated levels of serum LDH is reported very sensitive but not specific to indicate PCP. It is likely to be the result of the lung inflammation and injury, as also occurs in other lung diseases such as PTB and bacterial pneumonia (Carmona *et al.*, 2011; Crothers *et al.*, 2011; Kaur *et al.*, 2015).

The role of CD4⁺ T-cells is very important in the defense process against *P. jirovecii* infection. In most PCP studies, nearly all patients had CD4⁺ cell count <200 cells/mm³. The severity of CD4⁺ cell count impairment is associated with PCP severity, as well as the degree of lung inflammation severity. In excessive lung inflammation, gas exchange disorders can cause hypoxia, decreased lung compliance, even lead to respiratory failure (Kelly *et al.*, 2010; Carmona *et al.*, 2011).

A meta-analysis study on the use of sputum induction as the initial examination procedure of PCP reported 74–95% of sensitivity and reduce requirements of bronchoscopy procedure (Cruciani *et al.*, 2002). Monoclonal antibody detection of *P. jirovecii* with immunofluorescence staining

shows good results and can be compared with the histopathologic examination by silver staining (GMS). In many countries, several studies showed induced sputum and immunofluorescence staining as a recommended procedure to diagnose PCP in AIDS patients (Cruciani *et al.*, 2002; Choe *et al.*, 2014; Kaur *et al.*, 2015).

Development of the molecular method using PCR allows the diagnosis of PCP from more easily obtained clinical specimens, although not yet clearly distinguish between commensal and pathogens. Therefore, clinical correlation is always necessary. Real-time PCR allows a quantitative examination to distinguish commensal or subclinical infections with pathogens more quickly and precisely. However, some limitations should be considered, including standardizing the examination protocol that requires a specific technical skill, adequate facility support, and high costs of tool supply (Carmona *et al.*, 2011; Choe *et al.*, 2014; Kaur *et al.*, 2015; Song *et al.*, 2016).

Risk factors for PCP could not be determined in this study because the statistical tests showed no significant results, but low CD4⁺ cell count was considered as a possible risk factor. Studies to determine the risk factors of having PCP have been conducted and show various results, but only CD4⁺ cell count is widely reported as a major risk factor occurrence of PCP in AIDS patients (Kaplan *et al.*, 1998; Yanagisawa *et al.*, 2015).

The HIV-infected patients may suffer from PCP concurrently with PTB, especially in hyperendemic TB areas. Therefore, patients with diffuse pneumonia should be evaluated for *P. jirovecii* and *M. tuberculosis* from the beginning since dual infections might aggravate the patient's condition. When both microorganisms are found, then treatment for both diseases should be adequately administered. In patients who have either one of PCP or PTB infection, but showed no improvement or even clinical worsening despite apparently adequate treatment, we should consider the possibility of those concurrent infections (Castro *et al.*, 2007; Huang *et al.*, 2011).

Even though optimal therapy has been administered, but it seemed that patients could not survive due to very poor immune status, including very low CD4+ cell counts and advanced disease stages resulting in multiple complications. The possibility of other opportunistic infections caused by bacteria, viruses, parasites or other fungi, might worsen the patient's condition. The microorganism resistance is another issue to be taken into consideration although it could not yet be known due to limited facilities. Therefore, further study is needed to address all of these issues.

This was a preliminary study with a limited number of participants due to limited resources, facilities, and financial issues. Further study on PCP and or concurrent infection with PTB is needed using a prospective-analytic study, involving a larger number of participants, including more complete data collection on diagnostic procedures, risk factors, epidemiology, prognostic factors, and management. It is worth investigating the source of infection to make better prevention and management in the future.

In conclusion, the percentage of PCP in 55 HIV-infected patients in this study was 14.6% (8 out of 55 patients). The clinical manifestations showed weight loss, fever, shortness of breath, and crackles in all PCP patients, while dry cough in five patients. The most common chest x-ray feature was diffuse bilateral infiltrates. Furthermore, the percentage of PTB with positive AFB was 9.1% (5 out of 55 patients), and concurrent infection of *P. jirovecii* and *M. tuberculosis* was documented on those three out of five positive AFB patients. Severe immune disorders including very low CD4+ cell counts, advanced disease stages, and other complications might lead to deterioration of patient conditions. Early diagnosis is mandatory, begins with clinical suspicion, adequate laboratory testing, along with radiological examination. Induced sputum and immunofluorescence staining is a recommended procedure in diagnosing PCP in HIV-infected patients, particularly in limited facility situations.

Acknowledgement. The authors would like to thank all the medical staff and nurses from Cipto Mangunkusumo Hospital, Persahabatan Hospital, and Dharmais Hospital; as well as the laboratory staff of mycology laboratory, Department of Parasitology Faculty of Medicine, Universitas Indonesia.

Conflicts of interest

There are no conflicts of interest.

REFERENCES

- Aderaye, G., Bruchfeld, J., Assefa, G., Nigussie, Y., Melaku, K. & Woldeamanuel, Y. (2007). *Pneumocystis jirovecii* pneumonia and other pulmonary infections in TB smear-negative HIB-positive patients with atypical chest X-ray in Ethiopia. *Scandinavian Journal of Infectious Diseases* **39**: 1045-1053.
- Benito, N., Moreno, A., Miro, J.M. & Torres, A. (2012). Pulmonary infections in HIV-infected patients: an update in the 21st century. *European Respiratory Journal* **39**: 730-745.
- Butt, A.A., Michaels, S. & Kissinger, P. (2012). The association of serum lactate dehydrogenase level with selected opportunistic infections and HIV progression. *International Journal of Infectious Diseases* **6**: 178-181.
- Carmona, E.M. & Limper, A.H. (2011). Update on the diagnosis and treatment of *Pneumocystis pneumonia*. *Therapeutic Advances in Respiratory Diseases* **5**: 41-59.
- Castro, J.G., Manzi, G., Espinoza, L., Campos, M. & Boulanger, C. (2007). Concurrent PCP and TB pneumonia in HIV-infected patients. *Scandinavian Journal of Infectious Diseases* **39**: 1054-1058.
- Choe, P.G., Kang, Y.M., Kim, G., Park, W.B., Park, S.W. & Kim, H.B. (2014). Diagnostic value of direct fluorescence antibody staining for *Pneumocystis jirovecii* in expectorated sputum from patients with HIV Infection. *Medical Mycology* **52**: 326-330.

- Crothers, K., Thompson, B.W., Burkhardt, K., Morris, A., Flores, S.C. & Diaz, P.T. (2011). HIV-associated lung infections and complications in the era of combination antiretroviral therapy. *Proceeding of American Thoracic Society* **8**: 275-281.
- Cruciani, M., Marcati, P. & Malena, M. (2002). Meta-analysis of diagnostic procedures for *Pneumocystis carinii* pneumonia in HIV-1-infected patients. *European Respiratory Journal* **20**: 982-989.
- de Arma, Rodriguez, Y., Wissmann, G., Müller, A.L., Pederiva, M.A., Brum, M.C. & Brackmann, R.L. (2011). *Pneumocystis jirovecii* pneumonia in developing countries. *Parasite* **18**: 219-228.
- Hardak, E., Brook, O. & Yigla, M. (2010). Radiological features of *Pneumocystis jirovecii* pneumonia in immunocompromised patients with and without AIDS. *Lung* **188**: 159-163.
- Huang, L., Cattamanchi, A., Davis, J.L., den Boon, S., Kovacs, J. & Meshnick, S. (2011). HIV-associated *Pneumocystis* pneumonia. *Proceeding of American Thoracic Society* **8**: 294-300.
- Kaplan, J.E., Hanson, D.L., Navin, T.R. & Jones, J.L. (1998). Risk factors for primary *Pneumocystis carinii* pneumonia in human immunodeficiency virus-infected adolescents and adults in the United States: reassessment of indication for chemoprophylaxis. *Journal of Infectious Diseases* **178**: 1126-1132.
- Kaur, R., Wadhwa, A., Bhalla, P. & Dhakad, M.S. (2015). *Pneumocystis* pneumonia in HIV patients: a diagnostic challenge till date. *Medical Mycology* **53**: 587-592.
- Kelly, M.N. & Shellito, J.E. (2010). Current understanding of *Pneumocystis* immunology. *Future of Microbiology* **5**: 43-65.
- Lowe, D.M., Rangaka, M.X., Gordon, F., James, C.D. & Miller, R.F. (2013). *Pneumocystis jirovecii* pneumonia in tropical and low and middle income countries: a systematic review and meta-regression. *PLoS ONE* **8**: 1-14.
- Pandey, S., Ghosh, S., Halder, P., Pal, D., Modak, D.C. & Guha, S.K. Pulmonary tuberculosis and *Pneumocystis jirovecii* concurrent pneumonia in HIV infected patients at a resource limited setting in Eastern India: A case series. *Indian Journal of Tuberculosis* **67**(3): 378-382.
- Song, Y., Ren, Y., Wang, X. & Li, R. (2016). Recent advances in the diagnosis of *Pneumocystis* pneumonia. *Medical Mycology* **57**: E111-116.
- Trinh, Q.M., Nguyen, H.L. & Nguyen, V.N. (2015). Tuberculosis and HIV co-infection- focus on the Asia-Pacific region. *International Journal of Infectious Diseases* **32**: 170-178.
- Vogel, M., Weissgerber, P., Goeppert, B., Hetzel, J., Vatlach, M., Claussen, C. & Horger, M. (2011). Accuracy of serum LDH elevation for the diagnosis of *Pneumocystis jirovecii* pneumonia. *Swiss Medical Weekly* **141**: 1-4.
- World Health Organization. (2007). Improving the diagnosis and treatment of smear-negative pulmonary and extrapulmonary tuberculosis among adults and adolescents: recommendations for HIV-prevalent and resource-constrained settings / Stop TB Department; Department of HIV/AIDS. World Health Organization. <https://apps.who.int/iris/handle/10665/69463>
- Yanagisawa, K. & Nojima, Y. (2015). HIV and *Pneumocystis* pneumonia (PCP): an up-to-date. *Journal of Infectious Disease Therapy* **15**: 3-6.