

Enteric parasites of Egyptian captive birds: A general coprological survey with new records of the species

El-Shahawy, I.S.^{1*} and Abou Elenien, F.²

¹Department of Parasitology, Faculty of Veterinary Medicine, South Valley University, Egypt

²Department of Hygiene and Preventive Medicine, Faculty of Veterinary Medicine, Kafrelsheikh University, Egypt

*Corresponding author email: dr.ismail_para@yahoo.com

Received 12 March 2015; received in revised form 10 September 2015; accepted 12 September 2015

Abstract. A survey was undertaken to investigate the prevalence of intestinal parasites from various species of birds housed in a zoological garden in Egypt. A total of 72 faecal samples were collected randomly from studied birds. It was discovered that 63.9% were infected with at least one intestinal parasites, with 27.8% positive for helminths and 36.1% positive with protozoa. Coprological analysis revealed that the fecal samples were infected with different parasite species including 6 nematode eggs or larvae namely *Ascaridia* spp. (4.1%), *Heterakis* spp. (8.3%), *Capillaria* spp. (5.6%), *Contracaecum* spp. (2.8%), *Strongyloides avium* (2.8%), *Strongyloides pavenis* larvae (4.1%), 2 protozoan parasites identified were *Eimeria* spp. (25%) and *Cryptosporidium* spp. (11.1%). *Strongyloides pavenis*, *Contracaecum* spp. and *E. mutica* are referred for the first time in Egypt. New host record was established for most of these species. Routine monitoring for the presence of parasites in birds kept in the zoo is imperative in assisting zoo management and implementation of preventive and control measures against the spread of infectious parasitic diseases among birds within the zoo or to humans.

INTRODUCTION

In nature, wild birds live on large areas and have consequently have low genetic resistance against parasitic infections because of low exposure. When flocks of wild birds are kept in captivity in zoological gardens, the problem of parasitic infections can aggravate and pose a serious threat to endangered species, occasionally causing sudden and unexpected local declines in abundance (Muoria *et al.*, 2005). Gastro-intestinal parasites cause serious diarrhoea in birds. Under natural conditions, excessive infections of endoparasites seldom occur, whereas in caged or corralled birds, as in a zoo, the stress to which then birds are subjected weakens their immunological system, making them more susceptible to

parasite infection. Crowding, hygiene, and feeding are also key factors in the development of endoparasites in zoo animals (Malan *et al.*, 1997).

Due to increased risk of exposure, parasites can lead to serious problems or even death in birds recently brought into captivity, kept for prolonged periods in confined housings, and stressed due to injuries, illnesses, or adaptation to new environments (Smith, 1993; Lacina & Bird, 2000; Krone & Cooper, 2002).

Unfortunately, there have been few detailed and comprehensive studies on the prevalence of gastrointestinal parasites in birds housed in zoological garden. Therefore, the present study determines the prevalence of gastrointestinal parasites in the birds of the El-Gharbia Park, Egypt.

MATERIALS AND METHODS

Study area

This investigation was conducted at El-Gharbia city zoo located in the central region of Egypt. The park was officially opened in 1962 and has about 500 animals belonging to 100 species of mammals, birds, reptiles and amphibians.

Birds

This study covered various species of birds housed in El-Gharbia city zoo consisting of 30 Helmeted guinea fowl (*Numidia meleagirids*), 20 Indian peacocks (*Pavo cristatus*), 8 white peafowl, 7 Sparrows (*Java sparrows*), 4 Parrots (*Aratinga holochlora*) and 3 Ostrich (*Struthio camelus*) that were examined for the presence of parasitic infections. All the birds examined were adults and showed no symptoms for parasitic infections. Birds were housed in different cages based on their species either individually or in groups per cage.

Faecal samples collection

Faeces were collected off the ground in the morning with the assistance of the animal's handlers by utilizing sterile polystyrene spatulas immediately after visually observing a single bird defecates, multiple droppings were pooled from a single bird to collect an adequate amount of faeces (at least 2 grams) for parasitological examination. A new sterile spatula was used for each bird to avoid cross contamination. Individual faecal samples were labeled for each bird species and stored in insulated clean polythene bags, and then put in a cooler bag before being

transported to the parasitology laboratory Faculty of Veterinary Medicine, South Valley University, for a parasitological examination.

Laboratory Procedures

On arrival, each sample was preserved at +4°C before processing and examined by direct wet mount preparation, saturated salt solution floatation technique and permanent stains such as Modified Ziehl Neelsen stain according to the procedures carried by Dunn (1978); Kruse & Pritchard (1982) and Henriksen & Pholenz (1981).

RESULTS

I – Survey results

II – The overall intestinal parasitic infection in the present investigation was 63.9% with 27.8% positive for helminths and 36.1% positive for various species of protozoa as shown in Table 1. *Guinea fowl* had the highest infection rate with at least one intestinal parasite (80%), followed by Indian Peafowl (70%) and White Peafowl (62.5%), while Ostrich and Sparrows showed a low susceptibility to infection (33.3% and 24.9% respectively), with no record of parasitic infection among Parrot as shown in Table 1.

Generally, the present results indicated that protozoa infections were more prevalent compared to helminthes infections in the examined birds.

Coprological analysis revealed that the fecal samples were infected with different parasite species including 6 nematode eggs or larvae and 2 protozoan parasites.

Table 1. The overall occurrence (%) of intestinal parasitic infections among various Zoo birds

Birds	Sample size	Helminths positive (%)	Protozoa positive (%)	Total
Ostrich	3	0	1 (33.3)	1(33.3)
Sparrows	7	0	3 (42.9)	3(24.9)
Guinea fowl	20	16 (80)	0	16 (80)
Indian peafowl	30	4 (13.3)	17 (56.7)	21 (70)
White peafowl	8	0	5 (62.5)	5 (62.5)
Parrott	4	0	0	0
Total (Overall)	72	20 (27.8)	26 (36.1)	46 (63.9)

Among the coccidia identified were *Eimeria* spp. and *Cryptosporidium* spp., while the helminths identified were *Ascaridia* spp., *Heterakis* spp., *Capillaria* spp., *Contracaecum* spp. and *Strongyloides avium* and *Strongyloides paponis* larvae as depicted in Table 2.

In respect to protozoan parasites, the same table displayed that *Eimeria* species were the most prevalent species with an infection rate of 25%, while *Cryptosporidium* spp. was represented in 11.1% of the observed samples. Additionally the mean Emirian oocyst count was 2400 oocysts/g, while the oocyst load of *Cryptosporidium* spp. was very minimal since the smears revealed 2 oocysts /slide. Furthermore, five species of *Eimeria* were identified namely, *E. mandali*, *E. mayurai*, *E. pavonina*, *E. paponis* and *E. mutica* whereas their infection rates were 5.6%, 2.8%, 4.1%, 5.5% and 6.9% respectively and the later species was reported for the first time in Egypt with a new host record.

The helminths detected are shown in Table 2, *Heterakis* spp. was the most prevalent species (8.3%), while *Ascaridia* sp. and *Capillaria* spp. showed 4.1% and 5.6% prevalence. On the other hand, *Strongyloides avium* and *Strongyloides paponis* larvae were represented in 2.8% and 4.1% of the studied samples respectively and the later species was reported for the first time in

Egypt. Additionally, *Contracaecum* spp. was represented in 2.8% of the calculated data; this is the first report of the species in Egypt and a new host record is also established.

III – Morphological description of the recovered parasite species

Table (3 and 4) summarized the foremost morphological characters of the recovered parasite species in this study.

DISCUSSION

The effects of stress on the physiology and behaviour of birds as a consequence of their captivity, the proximity of the different bird cages, the housing of more than 1 bird per cage, and the poor hygienic conditions of the immediate surroundings of the birds are all factors conducive to rendering the birds susceptible to parasite infection (Varghese, 1987). The birds of the El-Gharbia Park were distributed in 6 cages. Most of these cages held more than 1 bird species. The hygienic conditions were relatively good, although the feeders and watering systems were situated inside the cages, implying continual faecal contamination. Consequently, prevalence of gastrointestinal parasites was 63.9%. Although the relationship between crowding of the birds and the prevalence of the

Table 2. Occurrence (%) of intestinal parasites in various birds at El-Gharbia city zoo

Birds	Number of examined birds	<i>Ascaridia</i> spp. egg	<i>Heterakis</i> spp. egg	<i>Capillaria</i> spp. egg	<i>Strongyloides paponis</i> larvae	<i>Strongyloides avium</i> larvae	<i>Contracaecum</i> spp. egg	<i>E. mandali</i>	<i>E. mayurai</i>	<i>E. pavonina</i>	<i>E. paponis</i>	<i>E. mutica</i>	<i>Cryptosporidium</i> spp. oocyst
		N (%)	N (%)	N (%)	N (%)	N (%)	N (%)	N (%)	N (%)	N (%)	N (%)	N (%)	N (%)
Ostrich	3	0	0	0	0	0	0	0	0	0	0	0	1 (33.3)
Sparrows	7	0	0	0	0	0	0	0	0	0	0	0	3 (42.8)
Guinea fowl	20	3 (15)	5 (25)	4 (20)	0	2(10)	2(10)	0	0	0	0	0	0
Indian peafowl	30	0	1 (3.3)	0	3 (10)	0	0	4 (13.3)	2 (6.7)	3 (10)	4 (13.3)	2 (6.7)	2(6.7)
White peafowl	8	0	0	0	0	0	0	0	0	0	0	3 (37.5)	2 (25)
Parrott	4	0	0	0	0	0	0	0	0	0	0	0	0
Total (overall)	72	3 (4.1)	6 (8.3)	4 (5.6)	3 (4.1)	2(2.8)	2 (2.8)	4 (5.6)	2 (2.8)	3 (4.1)	4 (5.5)	5 (6.9)	8 (11.1)

Table 3. Morphometric measurements of the recovered parasitic helminths form various Zoo birds

Parasitic forms	Host	Shape	Color	Length (µm)	Width (µm)	Remarks
<i>Ascaridia</i> spp. egg	Guinea fowl	Oval	Yellowish-white	70-85	42-48	Thick shell, smooth, three layers, slight barrel-shaped side-walls. Contents unsegmented. Plate 1, Fig. (1)
<i>Heterakis</i> spp. egg	Guinea fowl	Ellipsoidal	Yellowish-white	69-80	31-39	Shell thick, smooth side-walls. Contents unsegmented. Plate 1, Fig. (2)
<i>Capillaria</i> spp. egg	Guinea fowl	Lemon	Brown	44-60	20-35	Shell thick, smooth. Slightly barrel-shaped with asymmetrical side-walls. Two protruding polar plugs present. Contents granular, unsegmented. Plate 1, Figs. (3&4)
<i>Strongyloides avium</i> Larvae	Guinea fowl	Slender	Yellowish-brown	400-572	28	Length of oesphagous 157-259, length of tail 50-63. Plate 1, Figs. (6,7&8)
Newly recorded parasite species						
<i>Contracaecum</i> spp. egg	Guinea fowl	Spherical	Greyish	66-72	60-66	It has almost smooth sur-face. The hyaline wall of the egg shell appeared to be bilayered. When laid, the egg content was less often unsegmented or already at the morula stage. A small micropyle was present. Plate 1, Fig. (5)
<i>Strongyloides pavonis</i> larvae	Peafowl	Slender	Brown	570-647	17-21	Length of oesphagous 216-275, length of tail 60-89. Plate 1, Fig. (9&10)

Table 4. Morphometric measurements of the recovered parasitic protozoa form various Zoo birds

Parasitic species	Oocyst				Sporocyst		Remarks
	Shape	Size	Micropyl	Oocyst residuum	Shape	Size	
<i>E. pavonis</i>	Ovoid	20 -23 × 17	+	-	Ellipsoidal	12.1-15 × 6.6	Plate 2, Fig. (1)
<i>E. mandali</i>	Spherical	12-18 × 13-16	+	-	Ovoid	6 -11 × 4-7	Blue-pink Plate 2, Fig. (2)
<i>E. mayurai</i>	Ellipsoidal	23-25 × 13-15	+	-	Ovoid	10 -12 × 5-6	Plate 2, Fig. (4)
<i>E. pavonina</i>	Ovoid	20-26 × 16-18	+	+	Boat shaped	6 -15 × 4-8	Bright blue Plate 2, Fig. (5)
<i>Cryptosporidium</i> spp. oocyst	Oval	4.96 × 4.58	-	-	-	-	Bright rose-pink Plate 2, Figs. (6&7)
Newly recorded protozoa species							
<i>E. mutica</i>	Broadly Ellipsoid	23 -25 × 16-18	+	-	Elongate oval	12 -14 × 5-6	Plate 2, Fig. (3)

parasites was not studied, when cages were crowded, we consistently found intestinal parasites.

Among the intestinal parasites, protozoa were more prevalent than helminths, as expected, the appearance of these parasites can be explained by the simplicity of their life cycle, because they need no intermediate hosts and are immediately infective when excreted. Moreover, the low infective dose, the short prepatent period and ability to survive in the environment obviously ease transmission (Tanyuksel & Petri, 2003; Thompson & Monis, 2004).

Coccidiosis remains one of the most important diseases in the poultry industry, wreaking annual losses of millions of US dollars (Lopez *et al.*, 2007).

Coccidians are frequently seen in wild, domestic as well as caged and free birds (Lopez *et al.*, 2007; Perez Cordon *et al.*, 2008). Oocyst of *Eimeria* spp. was most prevalent among birds studied (25%), In the zoological garden Peña Escrita (Almuñecar, Spain) *Eimeria* sp. was the most prevalent species in birds (Perez Cordon *et al.*, 2008) with 16.6% of prevalence in Galliformes, Anseriformes and Struthioniformes. The lower prevalence in Peña Escrita Park may be due to the cleaner conditions in this park than in our study area, where the birds live in natural zones.

Occurrence of *Cryptosporidium* spp. was observed in most groups of birds studied. It was found that 11.1% of samples collected from various birds were positive with *Cryptosporidium* spp. Two studies at the same zoo have also detected *Cryptosporidium* in birds and have indicated a possible association of cryptosporidiosis among birds and their bird handlers (Rohela *et al.*, 2005; Lim *et al.*, 2007). Additionally, the prevalence of *Cryptosporidium* spp. in wild or captive birds varied in different countries, with the infection rate ranging from 1.4% to 7.2% in recent studies (Ng *et al.*, 2006; Ziegler *et al.*, 2007; Gul & Cicek, 2009; Majewska *et al.*, 2009; Nakamura *et al.*, 2009). This difference might be partially attributed to differences in sample collection as well as to hygienic measures applied. Hence, the ubiquitous

nature of *Cryptosporidium* in a zoological setup warrants further investigations.

Among helminths the most prevalent was *Heterakis* spp. (8.3%), the high rate of infection might be attributed to environmental condition such as moisture which supports larval development and facilitate transmission (Audu *et al.*, 2004). Furthermore, such guinea fowls and Indian peafowl could act as reservoirs of infection to locally domesticated chickens in this study area. Additionally, *Ascaridia* sp., with 4.1% prevalence, were frequent, too. This is normal, as *Ascaridia* is a frequent parasite in Psittaciformes and Galliformes, in which up to 7 species of *Ascaridia* have been found (Kajeroval *et al.*, 2004) as well as due to indiscriminate scavenging behaviour and poor sanitary measures as observed by Permin *et al.* (1997).

Capillariid eggs were very frequent findings (5.6%). The burrowing activity of *Capillaria* in the mucosa caused necrotic lesions. If the necrosis is severe enough, subsequent complications like diarrhoea, anorexia and cachexia, may develop. In our findings, sanitary measures are necessary as treatment, because *Capillaria* eggs are very durable and have an indirect life cycle. The survival of infective stages is in the intermediate hosts (the earthworm) is an important factor in the epizootology of capillariosis in gallinaceous birds (Moravec, 1982).

In the present investigation, *Strongyloides pavonis* has been recorded for the first time in the Indian peacocks, *Pavo cristatus*, in Egypt. Previously these helminth larvae were reported from the feces of green peacock, *Pavo muticus* in Southeast Asia via Hong Kong into the Maruyama Zoo, Sapporo (Sakamoto & Yamashita, 1970).

Additionally, *E. mutica* was reported for the first time in Egypt with a new host record (white peafowl) as it previously reported from the feces of green peacock, *Pavo muticus* in Saudi Arabia (Alyousif & Al-Shawa, 1998) as depicted in Table 5. The present description of these coccidian species is generally in agreement with the original one. However, size variation of oocysts (Table 4) may be

Table 5. Remarks on the newly recorded species with new host record

Species	Remarks			Locality
	New host	Previous host	Morphological characters	
<i>E. mutica</i>	White Peafowl	Green peacock (<i>Pavo muticus</i>)	<i>E. mutica</i> is distinguished from those eimerian species that have ovoid or spherical oocysts from peacock. The remaining species which resemble <i>E. mutica</i> by having ellipsoidal oocysts are <i>E. mayurai</i> and <i>E. riyadhae</i> . <i>E. mutica</i> differs from <i>E. mayurai</i> in being wider, having two polar granules, and possessing longer sporocysts. The sporozoite of <i>E. mutica</i> has one large globule at both ends rather than one globule at the broad end as in <i>E. mayurai</i> . Also <i>E. mutica</i> has a large prominent micropyle instead of the barely perceptible micropyle as in <i>E. mayurai</i> . <i>E. mutica</i> differs from <i>E. riyadhae</i> in having a micropyle and smaller oocysts.	Saudi Arabia
<i>Contraecaecum</i> spp.	Guinea fowl	Pelecaniformes	A small micropyle was present which considered as main characteristic feature.	Worldwide

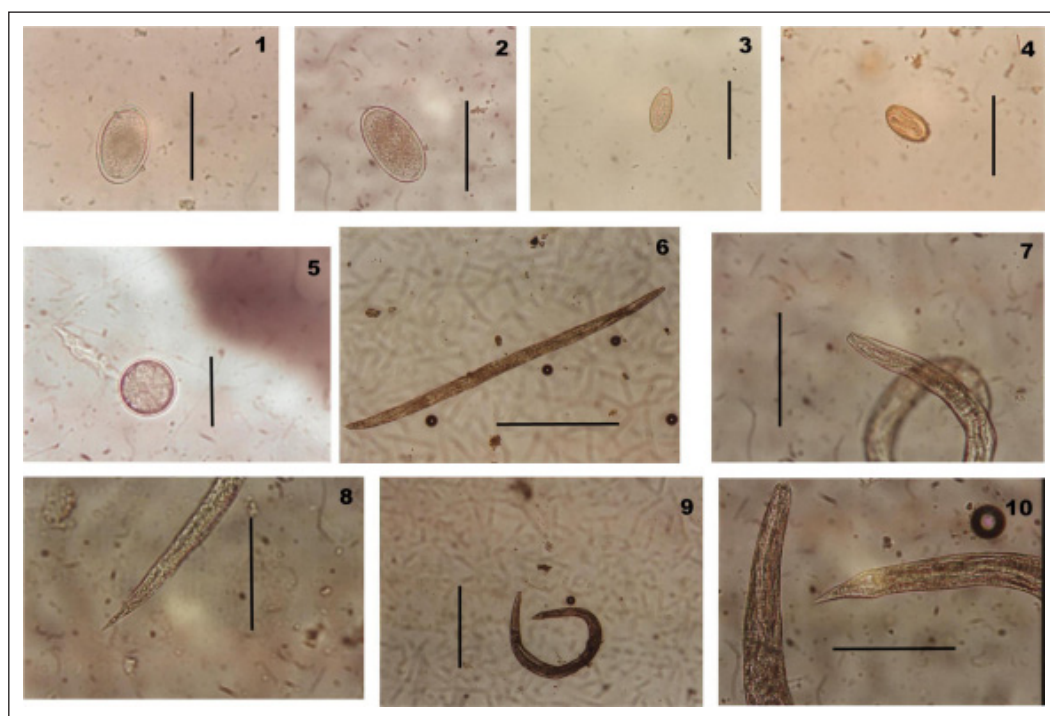


Plate 1. Helminths spp.

Figure 1. *Ascaridia* spp. egg (Scale bar = 50 µm)

Figure 2. *Heterakis* spp. egg (Scale bar = 50 µm)

Figure 3. *Capillaria* spp. egg (Scale bar = 50 µm)

Figure 4. *Capillaria* spp. egg containing infective larvae (Scale bar = 50 µm)

Figure 5. *Contraecaecum* spp. egg (Scale bar = 50 µm)

Figure 6. *Strongyloides avium* whole larvae (Scale bar = 100 µm)

Figure 7. *Strongyloides avium* anterior end (Scale bar = 100 µm)

Figure 8. *Strongyloides avium* posterior end (Scale bar = 100µm)

Figure 9. *Strongyloides pavonis* whole larvae (Scale bar = 50 µm)

Figure 10. *Strongyloides pavonis* anterior end & posterior end (Scale bar = 200 µm)

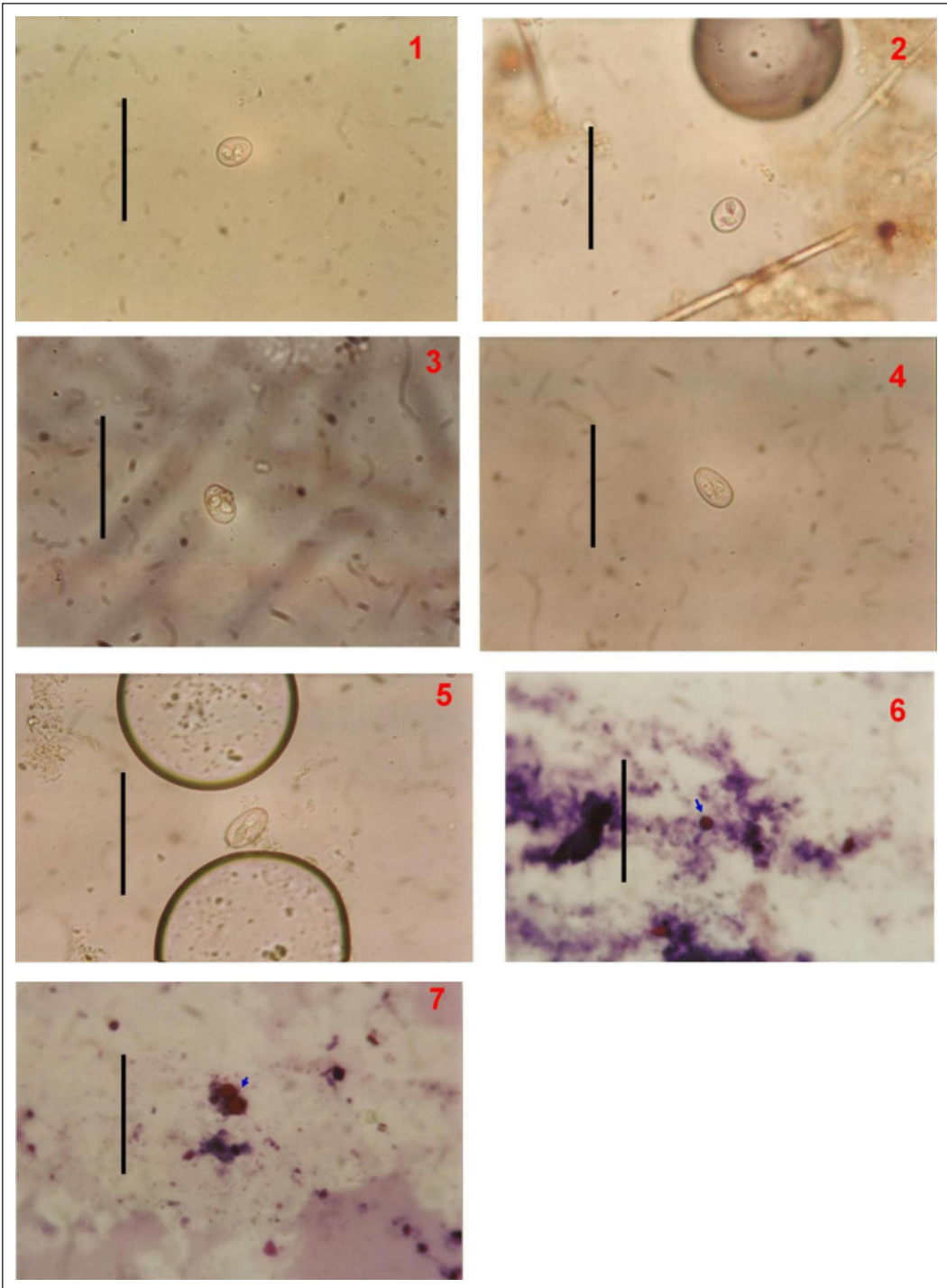


Plate 2. Protozoa spp.

Figure 1. *Eimeria pavonis* (Scale bar = 10 μ m)

Figure 2. *E. mandali* (Scale bar = 10 μ m)

Figure 3. *E. mutica* (Scale bar = 10 μ m)

Figure 4. *E. mayurai* (Scale bar = 10 μ m)

Figure 5. *E. pavonina* (Scale bar = 10 μ m)

Figure 6. *Cryptosporidium* spp. oocyst (Scale bar = 10 μ m)

Figure 7. *Cryptosporidium* spp. oocyst (2 oocyst/field; arrow) (Scale bar = 10 μ m)

due to the host and geographic distribution differences (Duszynski, 1971).

Regarding to *Contracaecum* spp. was reported for the first time in Egypt with a new host record (Guinea fowl) on worldwide basis, these species was described previously from fish-eating birds worldwide. This might be attributed to indiscriminate scavenging behaviour and poor sanitary measures as their food may contain infected fishes.

CONCLUSION

This study indicated the importance of monitoring levels of parasitic infections in zoological garden. The present study has found that 63.9% of captive birds were infected with various intestinal parasites as well as three newly recorded species with a new host record in Egypt was established. The results of this study showed that even with high standards of husbandry at El-Gharbia Zoo coupled with regular faecal examinations by the Veterinary Laboratory there remains a detectable level of parasitic infection. It is felt that if standards were lowered or husbandry or examination levels were relaxed a higher degree of infection would become evident. Some of intestinal parasites recorded in this study are known to be of human pathogenic importance as potential source for zoonotic transmission between animal and human especially among animal handlers.

Acknowledgements. To the reviewers, for a careful review of the manuscript and to their positive comments that substantially improved this paper.

REFERENCES

- Alyousif, M.S. & Al-Shawa, Y.R. (1998). Two new coccidia (Apicomplexa: Eimeriidae) from the green peacock (*Pavo muticus*) from Saudi Arabia. *Parasitology International* **47**: 301-306.
- Audu, P.A., Oniye, S.J. & Okechukwu, P.U. (2004). Helminthes parasites of domesticated pigeons (*Columbalivia domestica*) in Zaria. *Nigerian Journal of Pest Diseases and Vector Management* **5**: 356-360.
- Dunn, A.M. (1978). *Veterinary Helminthology*. 2nd ed. Butler and Tanner Ltd, Forme and London, Great Britain. pp. 3-88.
- Duszynski, D.W. (1971). Increase in size of *Eimeria separata* oocysts during patency. *Journal of Parasitology* **75**: 948-952.
- Gul, A. & Cicek, M. (2009). Investigation of the prevalence of gastrointestinal parasites in aviary birds in homes in the Van province. *Turkiye Parazitoloji Dergisi* **33**: 215-217.
- Henriksen, S.A. & Pholenz, J.F.L. (1981). Staining of Cryptosporidia by a modified Ziehl Neelsen technique. *Acta Veterinaria Scandinavica* **22**: 594.
- Kajerova, V., Barus, V. & Literak, I. (2004). Nematodes from the genus *Ascaridia* parasiting psittaciform birds: a review and determination key. *Veterinarni Medicina Czech* **49**(6): 217-223.
- Krone, O. & Cooper, J. (2002). Parasitic diseases, in *Birds of Prey: Health and Diseases*, J. E. Cooper, Ed., Blackwell Science, Oxford, UK, 3rd edition, pp. 105-120.
- Kurse, G.O.W. & Pritchard, M.H. (1982). The collection and preservation of animal parasites. Nebraska Univ. Press. USA.
- Lacina, D. & Bird, D. (2000). Endoparasites of raptors: a review and an update, in *Raptor Biomedicine III*, J.T. Lumeij, D. Remple, P.T. Redig, M. Lierz, and J.E. Cooper, Eds., Zoological Education Network, LakeWorth, Fla, USA, pp. 65-99.
- Lim, Y.A.L., Rohela, M. & Shukri, M. (2007). Cryptosporidiosis among birds and bird handlers at Zoo Negara, Malaysia. *Southeast Asian Journal of Tropical Medicine and Public Health* **38** (Suppl. 1): 19-26.

- Lopez, G., Figuerola, J. & Soriguer, R. (2007). Time of day, age and feeding habits influence coccidian oocyst shedding in wild passerines. *International Journal for Parasitology* **37**: 559-564.
- Majewska, A.C., Graczyk, T.K., Slodkiewicz-Kowalska, A., Tamang, L., Jedrzejewski, S., Zduniak, P., Solarczyk, P., Nowosad, A. & Nowosad, P. (2009). The role of free ranging, captive, and domestic birds of Western Poland in environmental contamination with *Cryptosporidium parvum* oocysts and *Giardia lamblia* cysts. *Parasitology Research* **104**: 1093-1099.
- Malan, F.S., Horak, I.G., Vos, V. & Van Wik, J.A. (1997). Wildlife parasites: lessons for parasites control in livestock. *Veterinary Parasitology* **71**: 137-153.
- Moravec, F. (1982). Proposal of a new systematic arrangement of nematodes of the family Capillariidae. *Folia Parasitologica* **29**: 119-132.
- Muoria, P.K., Muruthi, P., Rubenstein, D., Ogue, N.O. & Munene, E. (2005). Cross-sectional survey of gastro-intestinal parasites of Grevy's zebras in southern Samburu, Kenya. *African Journal of Ecology* **43**: 392-395.
- Nakamura, A.A., Simoes, D.C., Antunes, R.G., da Silva, D.C. & Meireles, M.V. (2009). Molecular characterization of *Cryptosporidium* spp. from fecal samples of birds kept in captivity in Brazil. *Veterinary Parasitology* **166**: 47-51.
- Ng, J., Pavlasek, I. & Ryan, U. (2006). Identification of novel *Cryptosporidium* genotypes from avian hosts. *Applied and Environmental Microbiology* **72**: 7548-7553.
- Perez Cordon, G., Hitos Prados, A., Romero, D., Sanchez Moreno, M., Pontes, A., Osuna, A. & Rosales, M.J. (2008). Intestinal parasitism in the animals of the zoological garden "Penã Escrita" (Almunãcar, Spain). *Veterinary Parasitology* **156**: 302-309.
- Permin, A., Magwisha, H., Kassuku, A.A., Nansen, M., Frandsen, F. & Gibb, L. (1997). A cross-sectional study of helminth in rural scavenging poultry in Tanzania its relation to season and climate. *Journal of Helminthology* **71**: 233-240.
- Rohela, M., Lim, Y.A. & Jamaiah, I. et al. (2005). Occurrence of *Cryptosporidium* oocysts in Wrinkled Hornbill and other birds in the Kuala Lumpur National Zoo, The Southeast Asian Journal of Tropical Medicine and Public Health, vol. 36, supplement 4, pp. 34-40.
- Sakamoto, T. & Yamashita, J. (1970). Studies on strongyloidiasis of the peacock: ii. *Strongyloides pavonis* n. sp. (nematoda: strongyloididae) from the green peafowl *pavo muticus* linnaeus. *Japanese Journal of Veterinary Research* **18**: 163-171.
- Smith, S.A. (1993). Diagnosis and treatment of helminthes in birds of prey, in Raptor Biomedicine, P.T. Redig, J.E. Cooper, J.D. Remple, and D.B. Hunter, Eds., University of Minnesota Press, Minneapolis, Minn, USA, pp. 21-27.
- Tanyuksel, M. & Petri, W. (2003). Laboratory diagnosis of amebiasis. *Clinical Microbiology Reviews* **16**: 713-729.
- Thompson, R.C.A. & Monis, P.T. (2004). Variation in *Giardia*: implications for taxonomy and epidemiology. *Advances in Parasitology* **58**: 69-137.
- Varghese, T. (1987). Endoparasites of birds of paradise in Papua New Guinea. *Veterinary Parasitology* **26**: 131-144.
- Ziegler, P.E., Wade, S.E., Schaaf, S.L., Stern, D.A., Nadareski, C.A. & Mohammed, H.O. (2007). Prevalence of *Cryptosporidium* species in wildlife populations within a watershed landscape in southeastern New York State. *Veterinary Parasitology* **147**: 176-184.