



## RESEARCH ARTICLE

# Increased risk of brucellosis misdiagnosis in regions that lose their endemicity

Bosilkovski, M.<sup>1\*</sup>, Khezzani, B.<sup>2</sup>, Vidinic, I.<sup>1</sup>, Jakimovski, D.<sup>1</sup>, Trajanovski, D.<sup>3</sup>, Poposki, K.<sup>1</sup>

<sup>1</sup>University hospital for infectious diseases and febrile conditions, Medical Faculty, "Ss Cyril and Methodius" University, Skopje, Republic of North Macedonia

<sup>2</sup>Department of Biology, Faculty of Natural and Life Sciences, El-Oued University, El-Oued, Algeria

<sup>3</sup>General hospital Kumanovo, Republic of North Macedonia

\*Corresponding author: milebos@yahoo.com

### ARTICLE HISTORY

Received: 13 January 2023

Revised: 27 January 2023

Accepted: 30 January 2023

Published: 31 March 2023

### ABSTRACT

Over the last decades, the epidemiology of human brucellosis globally has been subjected to significant changes, with the eradication of many existing endemic hot spots. This paper describes three cases with initial misdiagnosis of brucellosis that were managed during 2011-2017 in Republic of North Macedonia, country that until recently has been declared as endemic region. In spite of the fever, constitutional symptoms, focal disease (spondylitis, pneumonia and orchitis) and previous contact with domestic animals, brucellosis was not initially recognized, and patients were inadequately managed. Brucellosis should be part of differential diagnostic considerations in patients exposed to contacts with animals, with osteoarticular symptoms and signs, constitutional manifestations and different organ involvements in endemic regions where its incidence is diminishing.

**Keywords:** Brucellosis; spondylitis; epidemiology; endemic disease.

### INTRODUCTION

Human brucellosis is one of the most frequent zoonosis in the world (Khezzani *et al.*, 2021). It is mainly acquired through direct contact with infected animals or by consumption of improperly cooked food of animal origin or by inhalation of animal secretions (Bosilkovski, 2015; Khezzani *et al.*, 2020). Brucellosis is predominantly an endemic disease, but still in the last decades its endemic character has been subjected to permanent changes as a result of the current geopolitical and socioeconomic situation in the world, increased globalization as well as measures undertaken to improve its diagnosis and control (Pappas *et al.*, 2006; Bosilkovski *et al.*, 2018b). Therefore, in many countries where brucellosis was an endemic disease a few decades ago, nowadays the number of new cases is significantly small (Pappas *et al.*, 2006).

The Republic of North Macedonia (2 000 000 inhabitants) is one of these countries. The ministry of health reported a total of 10 772 cases of human brucellosis in the period 1990-2022. However, as shown on Figure 1, the annual number of cases decreased significantly from 922 in 1992 to 323 in 2005 to almost disappear in 2022 (only 2 cases) as a result of the Macedonian health authorities' efforts in brucellosis control (Bosilkovski *et al.*, 2018b).

Brucellosis is clinically manifested with general signs and symptoms without organ involvement, as a localized disease affecting certain organs and systems or as a combination of both presentations (Bosilkovski *et al.*, 2021). Localized brucellosis is found in 30-40% of cases (Colmenero *et al.*, 1996; Hasanjani Roushan *et al.*, 2004) and can affect different systems such as osteoarticular, hematopoietic, urogenital, nervous, respiratory, cardiovascular, gastrointestinal, as well as skin, eyes and thyroid gland (Bosilkovski, 2013; Cvetkova *et al.*, 2019). Thus, the spectrum of clinical presentations of brucellosis

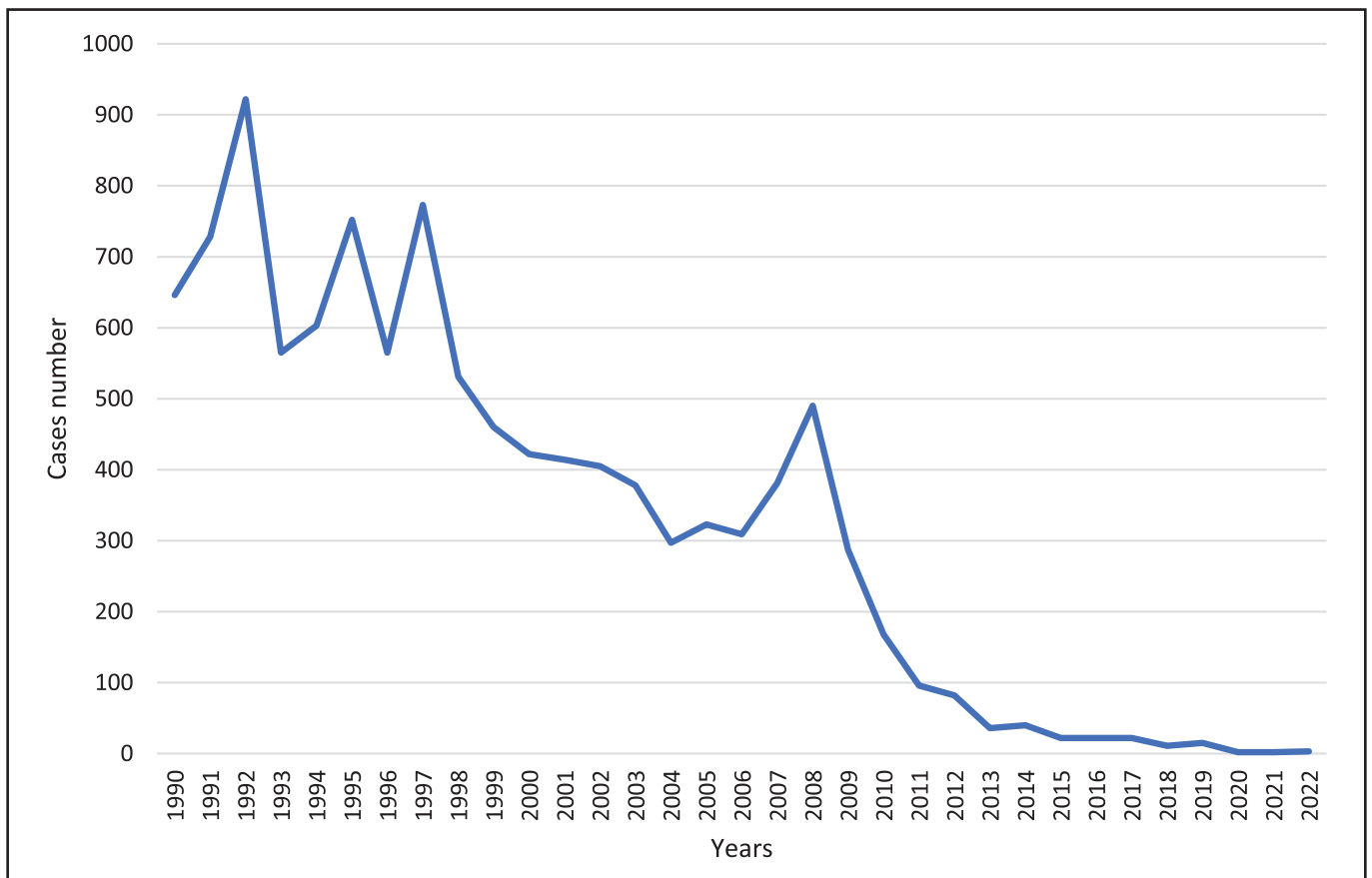
is diverse and non-specific (Battikh *et al.*, 2021) and quite often it is difficult to establish a clinical diagnosis (Orduña *et al.*, 2000).

Early diagnosis of the disease and treatment initiation leads to a higher rate of curability and less focal forms, therapeutic failures and chronicity (Bosilkovski *et al.*, 2019). In non-endemic, non-pastoral regions where doctors have no experience, brucellosis is very often misdiagnosed (Zheng *et al.*, 2018; Hassouneh *et al.*, 2019). In such cases, diagnosis is made mainly accidentally, after conducting extensive investigations by routinely made microbiological assays of cultures (Norman *et al.*, 2016). In endemic countries, diagnosis is reached relatively easy having in mind that doctors are familiarized with the disease and the use of diagnostic tests for brucellosis is often a routine procedure. Sometimes diagnostic difficulties emerge in regions where until recently this disease has been endemic and its incidence has been significantly reduced in the last years. For example, in Spain, brucellosis was a secondary diagnosis in up to one-third of 5 598 registered cases between 1997 and 2015 (Rodríguez-Alonso *et al.*, 2021).

We present three cases with a localized form of brucellosis with initial misdiagnosis in an endemic region that few years ago was among the leading regions according to the incidence worldwide (Pappas *et al.*, 2006; Bosilkovski *et al.*, 2018b). The study was approved by the Ethics Committee of the Medical Faculty in Skopje and all patients provided written consent for publishing their medical histories.

### PRESENTATION OF CASES

**Case 1.** A 69-year-old retired person was hospitalized in July-August 2013. The disease had begun three months prior to admission, gradually, by showing signs of sleepiness, malaise, decreased



**Figure 1.** Annually distribution of human brucellosis cases in the Republic of North Macedonia (1990-2022).

appetite, headache and excessive night sweating. Patient's body temperature ranged between 38 and 38.5°C, lasted for 2-3 weeks with intermittent afebrile periods in duration of 1-2 weeks. Two months prior to admission the patient complained of low back pain, which was intense when he was active and was reduced while he rested. The patient could not bend forward and could not turn himself in bed. At the same time, he experienced morning stiffness in the wrists, knees and ankles, which was diminishing during the day. Spinal pain progressed; it showed lumbar irradiation and the patient had a feeling of great discomfort. He lost 14 kg body weight during a three-month period. He was examined several times by an orthopedic surgeon and was treated with non-steroidal anti-inflammatory drugs for lumbar spondylosis, but without clinical improvement. Erythrocyte sedimentation rate (ESR) was 100 mm/h, hemoglobin (Hb) 116 g/L, red blood cells (RBC)  $3\ 800 \times 10^{12}/L$ , white blood cells (WBC)  $7.9 \times 10^9/L$ , platelets  $302 \times 10^{12}/L$ , neutrophils (Ne) 39%, lymphocytes (Ly) 48%, monocytes (Mo) 12%, creatinine 59  $\mu\text{mol}/L$ , alanin aminotransferase (ALT)/aspartat aminotransferase (AST) 21/28 U/L, C-reactive protein (CRP) 90 mg/L.

Two and a half months after the beginning of symptoms ischialgia in the right leg appeared and hence, CT of thoracic lumbosacral spine was made. It showed bone destruction of lumbar vertebrae from L2 to L5 with protrusion and penetration of the cortex, epiphysitis, ventral osteophytes and involvement of the neighboring intervertebral discs. Three blood cultures and molecular test for tuberculosis were negative and suspicion of brucellosis appeared, which was confirmed with positive Rose Bengal and Brucellacapt test (1/5 120) (Brucellacapt is considered positive in titer higher than 1/320). Further detailed epidemiological survey revealed that the patient was a member of a family involved in raising 150 sheep and three goats for years before. He was engaged in the work with the animals and he occasionally ate young cheese

prepared traditionally from unpasteurized milk. There were no other family members with health problems. On admission, the patient was adynamic, with temperature of 37.8°C. Moderate pain (5-6 numeric pain rating scale) was registered in the low thoracic and lumbar spine and it was most prominent on pressure of the fourth lumbar vertebra. Muscle spasm in the lumbar spine and limitation when bending forward were evident. There were no specific abnormal neurological manifestations.

Immediately upon admission, the patient was treated with gentamicin 120 mg two times a day for 10 days, along with oral doxycycline 200 mg once a day and 500 mg oral ciprofloxacin two times a day, both throughout the entire hospital stay (14 days). Non-steroid anti-inflammatory drug was added during the hospital stay and in the first ten days of post-hospital care. In the first two hospital days the patient had temperature up to 39.5°C; the following four days the temperature was up to 38.5°C; then until the discharge he was afebrile, with gradual reduction and disappearance of constitutional symptoms and a significant regression of spinal manifestations. The patient continued to be treated at home orally with doxycycline and ciprofloxacin.

On the first check-up, one month after hospital discharge, the patient's condition was significantly improved, with permanent but weak pains in the low back and with reduced, but still present muscle spasm in the same region. Serology showed Rose Bengal positivity and Brucellacapt test 1/5 120. On the next check-up, two months later, Rose Bengal and Brucellacapt test were positive and 1/1 280, respectively, with completely resolved muscle spasm and spinal mobility. Treatment with doxycycline and ciprofloxacin was continued for one more month (up to four and a half months) and then interrupted. The patient returned to his daily working activities with the small ruminants. Five months after hospitalization, biochemical and hematological parameters were within the normal

range, and serology analysis of brucellosis showed Rose Bengal positivity and Brucellacapt test 1/640. The patient was advised to make a spinal MRI, but he refused.

**Case 2.** A 65-year-old housewife was treated in a hospital in June 2011. The disease had started four weeks prior to admission with elevated temperature to 38.5°C, malaise, headache, decreased appetite, night sweats, migratory joint pains that were most prominent in the knees, ankles and wrist joints as well as with dry nonproductive cough. For more than five years she had a non-vaccinated cow, pasture-raised nearby the neighboring goats. The patient did not eat raw products of animal origin. Her husband did not present with any health problems. The laboratory analysis by the end of the first week of onset of symptoms showed ESR 25 mm/h, Hb 162 g/L, RBC 5 930x10<sup>12</sup>/L, WBC 10.1x10<sup>9</sup>/L, platelets 336x10<sup>12</sup>/L, Ne 45%, Ly 47%, Mo 4%, urea 3.3 mmol/L, ALT/AST 19/15 U/L, CRP 26 mg/L. Chest x-ray finding was suspicious for bronchopneumonia. It was assumed that the patient had community-acquired pneumonia and was treated with azithromycin of 500 mg once a day within the course of the first 3 days along with cefixime of 400 mg once a day for 14 days. During the treatment, the headache and malaise were reduced, the appetite increased, but body temperature of 38.0°C persisted as well as dry cough and migratory joint pains. Thus, two weeks after establishing the diagnosis of pneumonia, additional serological tests were made for respiratory agents, HIV, Lyme's disease and brucellosis and sputum for detection of tuberculosis. The results obtained were negative except for a positive finding for Rose Bengal and Brucellacapt test of 1/5 120. The patient was hospitalized and was initiated per oral treatment with 200 mg doxycycline once a day and 500 mg ciprofloxacin two times a day for six weeks. Body temperature returned to normal three days after initiation of this treatment, and cough relief and complete disappearance of all constitutional symptoms was achieved on the tenth day. Further follow-up showed regression of Brucellacapt test to 1/1 280, 1/640 and 1/320 - six, 15 and 36 months, respectively, after treatment was initiated. During the entire period of her follow-up, the patient suffered from moderate to mild joint pains.

**Case 3.** A 48-year-old man was treated on an outpatient basis in November 2017. The disease started suddenly, one month prior to his referral to our hospital. He presented with elevated body temperature of 39.5°C, pains in the shoulders and excessive sweating for which he had to change his clothes 4-5 times during one night. In the beginning of the disease, he also suffered from severe pain in his left testicle, which was enlarged. By the end of the first week his testicle became twice larger than the right one; it was painful, swollen and warm to the touch. The patient had harsh pains in the scrotum area especially while standing and walking. From the second to the seventh day, he was treated with gentamicin injections of 120 mg and amoxicillin/clavulanate tablets of 1 000 mg, both two times a day, but without improvement. On the seventh day since the onset of the symptoms, the patient was referred to a urology specialist and under suspicion of testicular infarction orchiectomy was immediately made. The removed testicle was with dimensions 6x4x4 cm, completely inflamed, with inconsistent surface and grayish-brownish coloring. Histopathological finding revealed testicular necrosis with inflammatory substrate that spread to the epididymis. The finding was accompanied with zones of bleeding. In the postoperative period, the patient received tablets cefixime of 400 mg once a day in a period of 10 days. He continued with elevated body temperature two more weeks post-surgery. Following orchiectomy, the patient continued to have excessive sweating and pains in the shoulders and he lost 6-7 kg body weight. This time asked for more details, he said he worked as a butcher involved in slaughtering and processing of lambs, goats and pigs during the last 30 years. His laboratory results yielded Hb 132 g/L, RBC 4 740x10<sup>12</sup>/L, WBC 5.1x10<sup>9</sup>/L, platelets 277x10<sup>12</sup>/L, Ne 58%, Ly 34%,

Mo 7%, creatinine 58 µmol/L, ALT/AST 38/28 U/L and CRP 6 mg/L. Serological test for brucellosis showed positive Rose Bengal and Brucellacapt test 1/2 560. The patient was treated per orally with doxycycline 200 mg once a day and ciprofloxacin 500 mg two times a day during eight weeks. After initiation of treatment, sweating lasted for one more week, and pains in the shoulders persisted for one more month. In the control follow-up period, no difficulties were observed. At three, six and 16 months after treatment Brucellacapt test was 1/640, 1/320 and 1/320, respectively.

## DISCUSSION

Brucellar spondylitis (diagnosed in Case 1) defined as inflammatory back pain and stiffness along with radiological, CT or MRI changes of the spine during brucellosis is one of the more serious complications of human brucellosis and one of the most incapacitating and painful maladies that can afflict man (Solera *et al.*, 1999). Brucellar spondylitis is the main cause of therapeutic failures and sequelae in these patients (Bosilkovski *et al.*, 2004). Its prevalence ranges from 3% to 65% and is predominantly found in older patients and patients with longer illness duration before establishing the diagnosis (Solera *et al.*, 1999; Bosilkovski *et al.*, 2004).

The spectrum of the symptoms and signs in spondylitis early in the course of brucellosis is nonspecific and subtle. Elevated temperature and constitutional difficulties are encountered in 32% and 85% of patients, respectively (Colmenero *et al.*, 1992; Solera *et al.*, 1999). Radiographic and CT findings of brucellar spondylitis are intervertebral disk involvement, epiphysitis of the antero-superior angle, osteolysis of the vertebral body and dense sclerosis (Bosilkovski *et al.*, 2004).

Our case, according to many parameters such as endemic region, age, occupational exposure, characteristics and localization of back pains accompanied with long-term fever, constitutional and joint difficulties was supposed to be an easy diagnostic puzzle (Esmailnejad-Ganji & Esmailnejad-Ganji, 2019). However, this patient was inadequately treated as spondylosis and ishialgia and the diagnosis was established very late and by reverse order than the usual one - the accidental CT finding raised suspicions and initiated diagnostic procedures for brucellosis detection.

Pulmonary involvement (as in Case 2) occurs in 1-7% of patients with brucellosis. Bronchitis, interstitial pneumonitis, lobar pneumonia, lung nodules, pleural effusion, hilar lymphadenopathy, empyema, or abscesses have been reported (Pappas *et al.*, 2003; Bosilkovski, 2013), and sometimes it is difficult initially to differentiate respiratory brucellosis from tuberculosis or other community acquired pneumonia forms (Madkour & Al-Saif, 2001; Pappas *et al.*, 2003).

Our case was initially comprehended as a community-acquired pneumonia due to the chest x-ray finding and combined symptomatology of moderate respiratory and general symptoms; it had an unfavorable response to the standard empiric treatment for community-acquired pneumonia, but had a good response to the treatment for brucellosis. The fact that in the initial diagnostic considerations, endemic region and close contact with animals was not taken into consideration led to under recognized brucellosis and to diagnostic and therapeutic delay.

Genitourinary involvement (characteristic for Case 3) occurs in 2-25% of cases (Bosilkovski *et al.*, 2018a). Unilateral epididymo-orchitis as the most common form of genitourinary localization of brucellosis may occur as an isolated brucellar manifestation or it might be within a systemic generalized disease (Bosilkovski *et al.*, 2018a). Tumor, tuberculosis or other causes may be mistakenly diagnosed, and unnecessary orchiectomy may be carried out (Madkour *et al.*, 2001) as in our example.

Our patient was unnecessary subjected to surgical intervention not taking into account the concomitant presence of general and articular symptoms, endemicity of the region and patient's

professional occupation. The persistence of some of the symptoms after the completed surgical intervention as well as the delayed data regarding his occupation were the reason for broadening the differentially diagnostic considerations and delayed establishment of the etiological diagnosis.

Initial misdiagnosis was common for all described cases, in spite of the fact that the patients had a permanent contact with domestic animals and long-term fever accompanied with sweating, articular symptoms and other constitutional difficulties as well as involvement of certain organ system in a region that until recently has been considered to be among the leading ones in the world for the incidence of human brucellosis.

The negligence of these clinical and epidemiological data along with the non-specific hematological and biochemical analyses and non-routine use of blood cultures in diagnostic aims were the reason for misdiagnosis of brucellosis. This consequently led to unnecessary examinations and inadequate therapeutic procedures that were ineffective. Fortunately, regardless the fact that there was delayed diagnostics in the presented cases, due to the adequate treatment no unfavorable outcome was registered.

## CONCLUSION

In spite of the fact that over the last years the incidence of human brucellosis has been significantly reduced in the Republic of North Macedonia, brucellosis has to remain a constituent segment of the differential diagnostic considerations in conditions which include fever and organ involvement. Furthermore, regular questioning about patients' profession and possible contact with animals should not be left out, and serology and bacterial culture tests have to be a constituent segment of the routine diagnostic protocols.

## Conflict of interest

The author declares that they have no conflict of interests.

## REFERENCES

- Battikh, H., Berriche, A., Zayoud, R., Ammari, L., Abdelmalek, R., Kilani, B., Tiouiri Ben Aissa, H. & Zribi, M. (2021). Clinical and laboratory features of brucellosis in a university hospital in Tunisia. *Infectious Diseases Now* **51**: 547-551. <https://doi.org/10.1016/j.idnow.2021.03.005>
- Bosilkovski, M. (2015). Brucellosis: It is not only Malta! In: *Zoonoses - Infections Affecting Humans and Animals: Focus on Public Health Aspects*, Sing, A. (editor). Dordrecht, Netherlands: Springer, pp. 287-315. [https://doi.org/10.1007/978-94-017-9457-2\\_11](https://doi.org/10.1007/978-94-017-9457-2_11)
- Bosilkovski, M. (2013). Microbiology, epidemiology, and pathogenesis of Brucella. Retrieved from UpToDate website: <http://www.uptodate.com/contents/microbiology-epidemiology-andpathogenesis-of-brucella/abstract/59>
- Bosilkovski, M., Kamiloski, V., Miskova, S., Balalovski, D., Kotevska, V. & Petrovski, M. (2018a). Testicular infection in brucellosis: report of 34 cases. *Journal of Microbiology, Immunology and Infection* **51**: 82-87. <https://doi.org/10.1016/j.jmii.2016.02.004>
- Bosilkovski, M., Keramat, F. & Arapović, J. (2021). The current therapeutical strategies in human brucellosis. *Infection* **49**: 823-832. <https://doi.org/10.1007/s15010-021-01586-w>
- Bosilkovski, M., Krteva, L., Caparoska, S. & Dimzova, M. (2004). Osteoarticular involvement in brucellosis: study of 196 cases in the Republic of Macedonia. *Croatian Medical Journal* **45**: 727-733.
- Bosilkovski, M., Siskova, D., Spasovska, K., Vidinic, I. & Dimzova, M. (2019). The influence of illness duration before diagnosis on clinical characteristics and outcome in human brucellosis. *Tropical Doctor* **49**: 177-181. <https://doi.org/10.1177/0049475519846422>
- Bosilkovski, M., Stojanov, A., Stevanovic, M., Karadzovski, Z. & Krstevski, K. (2018b). Impact of measures to control brucellosis on disease characteristics in humans: experience from an endemic region in the Balkans. *Infectious Diseases* **50**: 340-345. <https://doi.org/10.1080/23744235.2017.1407037>
- Colmenero, J.D., Orjuela, D.L., Garcia-Portales, R., Juarez, C., Rodriguez-Sampedro, F., Cisneros, J.M. & Pachón, J. (1992). Clinical course and prognosis of Brucella spondylitis. *Infection* **20**: 38-42. <https://doi.org/10.1007/BF01704893>
- Colmenero, J.D., Reguera, J.M., Martos, F., Sánchez-De-Mora, D., Delgado, M., Causse, M., Martín-Farfán, A. & Juárez, C. (1996). Complications associated with Brucella melitensis infection: a study of 530 cases. *Medicine* **75**: 195-211. <https://doi.org/10.1097/00005792-199607000-00003>
- Cvetkova, M., Bitoska, I., Poposki, K., Jakimovski, D. & Bosilkovski, M. (2019). Acute thyroiditis associated with brucellosis: a case report. *Prilozi (Makedonska akademija na naukite i umetnostite. Oddelenie za medicinski nauki)* **40**: 113-117. <https://doi.org/10.2478/prilozi-2019-0022>
- Esmaeilnejad-Ganji, S.M. & Esmaeilnejad-Ganji, S.M.R. (2019). Osteoarticular manifestations of human brucellosis: a review. *World Journal of Orthopedics* **10**: 54-62. <https://doi.org/10.5312/wjo.v10.i2.54>
- Hasanjani Roushan, M.R., Mohrez, M., Smailnejad Gangi, S.M., Soleimani Amiri, M.J. & Hajjahmadi, M. (2004). Epidemiological features and clinical manifestations in 469 adult patients with brucellosis in Babol, Northern Iran. *Epidemiology and Infection* **132**: 1109-1114. <https://doi.org/10.1017/S0950268804002833>
- Hassouneh, L., Quadri, S., Pichilingue-Reto, P., Chaisavaneeyakorn, S., Cutrell, J.B., Wetzel, D.M. & Nijhawan, A.E. (2019). An outbreak of brucellosis: an adult and pediatric case series. *Open Forum Infectious Diseases* **6**. <https://doi.org/10.1093/ofid/ofz384>
- Khezzani, B., Aouachria, A.N., Djaballah, S., Djedidi, T. & Bosilkovski, M. (2020). An overview of animal brucellosis in the province of El-Oued (Algerian Sahara). *Journal of Fundamental and Applied Sciences* **12**: 225-244. <https://doi.org/10.4314/jfas.v12i15.16>
- Khezzani, B., Aouachria, A.N., Khechekhouche, E.A., Djaballah, S., Djedidi, T. & Bosilkovski, M. (2021). Caractéristiques épidémiologiques de la brucellose humaine dans la province d'El-Oued, sud-est algérien. *Santé Publique* **33**: 275-284. <https://doi.org/10.3917/spub.212.0275>
- Madkour, M.M., Al-Otaibi, K.E., Al-Ahmary, S., Al-Sabaan, F. & Al-Wahhabi, B. (2001). Genitourinary brucellosis. In: *Madkour's Brucellosis*, Madkour, M.M. (editor). Berlin, Heidelberg: Springer, pp. 159-165. [https://doi.org/10.1007/978-3-642-59533-2\\_14](https://doi.org/10.1007/978-3-642-59533-2_14)
- Madkour, M.M. & Al-Saif, A. (2001). Respiratory brucellosis. In: *Madkour's Brucellosis*, Madkour, M.M. (editor). Berlin, Heidelberg: Springer, pp. 144-149. [https://doi.org/10.1007/978-3-642-59533-2\\_12](https://doi.org/10.1007/978-3-642-59533-2_12)
- Norman, F.F., Monge-Maillo, B., Chamorro-Tojeiro, S., Pérez-Molina, J.-A. & López-Vélez, R. (2016). Imported brucellosis: a case series and literature review. *Travel Medicine and Infectious Disease* **14**: 182-199. <https://doi.org/10.1016/j.tmaid.2016.05.005>
- Orduña, A., Almaraz, A., Prado, A., Gutierrez, M.P., Garcia-Pascual, A., Dueñas, A., Cuervo, M., Abad, R., Hernández, B., Lorenzo, B. et al. (2000). Evaluation of an immunocapture-agglutination test (Brucellacapt) for serodiagnosis of human brucellosis. *Journal of Clinical Microbiology* **38**: 4000-4005. <https://doi.org/10.1128/JCM.38.11.4000-4005.2000>
- Pappas, G., Bosilkovski, M., Akritidis, N., Mastora, M., Krteva, L. & Tsianos, E. (2003). Brucellosis and the respiratory system. *Clinical Infectious Diseases* **37**: e95-e99. <https://doi.org/10.1086/378125>
- Pappas, G., Papadimitriou, P., Akritidis, N., Christou, L. & Tsianos, E.V. (2006). The new global map of human brucellosis. *The Lancet Infectious Diseases* **6**: 91-99. [https://doi.org/10.1016/s1473-3099\(06\)70382-6](https://doi.org/10.1016/s1473-3099(06)70382-6)
- Rodriguez-Alonso, B., Almeida, H., Alonso-Sardón, M., Velasco-Tirado, V., Romero-Alegria, Á., Pardo-Lledias, J., López-Bernus, A., Pérez Arellano, J.L. & Belhassen-García, M. (2021). Epidemiological assessment of 5598 brucellosis inpatients in Spain (1997-2015). *Epidemiology and Infection* **149**: e149. <https://doi.org/10.1017/S0950268821001151>
- Solera, J., Lozano, E., Martínez-Alfaro, E., Espinosa, A., Castillejos, M.L. & Abad, L. (1999). Brucellar spondylitis: review of 35 cases and literature survey. *Clinical Infectious Diseases* **29**: 1440-1449. <https://doi.org/10.1086/313524>
- Zheng, R., Xie, S., Lu, X., Sun, L., Zhou, Y., Zhang, Y. & Wang, K. (2018). A systematic review and meta-analysis of epidemiology and clinical manifestations of human brucellosis in China. *BioMed Research International* **2018**: 5712920. <https://doi.org/10.1155/2018/5712920>